



## Esthetic Gingival Depigmentation and Smile Line Correction Using Diode Laser: A Case Report

<sup>1</sup>Dr. Kashif Ahmad, <sup>2</sup>Dr. Anand Kishore, <sup>3</sup>Dr. Komal S. Sharma, <sup>4</sup>Dr. Sudhanshu Agrawal, <sup>5</sup>Dr. Sourav Chowdhury

<sup>1,5</sup>Pg Student ( JR I), <sup>2</sup>Head of Department, <sup>3</sup>Assistant Professor, <sup>4</sup>Associate Professor  
Department of Periodontology, Chandra Dental College & Hospital, Barabanki, India

**\*Corresponding Author:  
Dr. Sudhanshu Agrawal**

Associate Professor, Department of Periodontology, Chandra Dental College & Hospital, Barabanki, India

Type of Publication: Case Report

Conflicts of Interest: Nil

### Abstract

Disproportionally small teeth and gingival hyperpigmentation are major concerns for a large number of young patients visiting the dentist. Melanin hyperpigmentation usually does not present a medical problem, but patients usually complain of dark gums as unaesthetic. This problem is aggravated in patients with uneven smile line. esthetic periodontal plastic surgery is especially rewarding in such individuals with compromised esthetics. A case is reported here on the cosmetic correction of “Black Gums” and “Uneven Smile Line.” periodontal plastic surgery combining gingival depigmentation and esthetic crown lengthening was performed in a single appointment using diode laser.

**Keywords:** Gingival Pigmentation, Gingival Depigmentation, Periodontal Plastic Surgical Procedures, Anterior Esthetic Crown Lengthening, Lasers in Periodontal Surgery

### Introduction

Melanin, a brown pigment, is the most common cause of endogenous pigmentation of gingiva and is the most predominant pigmentation of mucosa.<sup>1,2</sup>

Gingival Hyperpigmentation is seen as a genetic trait in some populations and is more appropriately termed physiologic or racial gingival pigmentation.<sup>3,4</sup>

Gingival Depigmentation is a periodontal plastic surgical procedure whereby the gingival hyperpigmentation is removed or reduced by various techniques. The first and foremost indication for depigmentation is patient demand for improved esthetics.

### Methods of Gingival Depigmentation<sup>5</sup>

#### A. Surgical Methods of Depigmentation

1. Scalpel Surgical Technique
2. Cryosurgery

#### 3. Electrosurgery

#### 4. Lasers

1. Neodymium: Aluminum-Yttrium-Garnet (Nd:YAG) Lasers
2. Erbium (Er:YAG) Lasers
3. Carbon Dioxide (CO<sub>2</sub>) Lasers

#### 5. Diamond Burs

B. Methods aimed at masking the pigmented gingiva with grafts from less pigmented areas.

1. Free Gingival Grafts
2. Acellular Dermal Matrix Allograft.

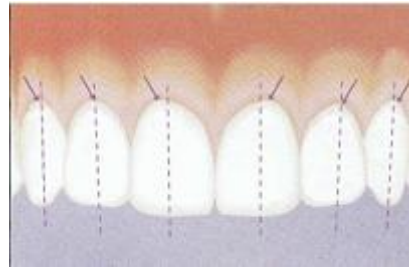
Laser Depigmentation has become widely used recently and is even preferred over scalpel technique by many clinicians. The documented advantages of lasers in periodontal surgery include less bleeding and reduced postoperative pain.<sup>6</sup> Accelerated wound healing with laser use has not been scientifically

validated. negative effects of lasers, especially Nd:YAG and CO<sub>2</sub> lasers, include thermal damage to underlying bone when these lasers are used on thin soft tissue during gingivectomies. Tissue penetration from the laser may cause thermal damage 2 to 4 mm Below the surface, causing underlying hard tissue damage.<sup>7</sup>

Focus for many general dentists has been on the tooth structure and reshaping incisal edges, but gingival recontouring of soft tissues can yield better length to width proportions on teeth. A focus on gingival shape

and gingival contour is essential when altering soft tissue proportions of anterior teeth.

Many of these principles are covered through cosmetic dentistry articles dealing with smile design.<sup>8</sup> Generally, the gingival heights of the maxillary centrals should be symmetrical in shape, and correspond to the height of the canines, whereas the lateral incisors can be 0.5-1 mm more coronal. The zeniths of the soft tissue curvature should be slightly distal to the long axis of the teeth, (Figure 1) and the width of the tooth should be 75-80% of the length of the tooth.



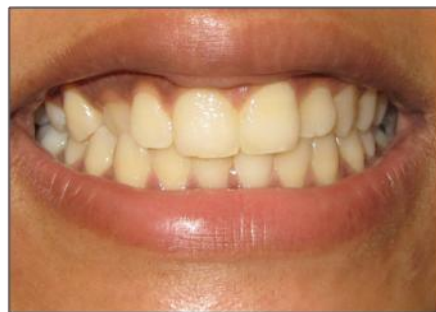**Fig. 1**

Therefore, the diode laser can be used to help with: (1) Improving Gingival Shape and Contour, (2) Lengthening Crowns, (3) Idealizing Tooth Proportionality, and (4) Resolving Crown/Height Asymmetries

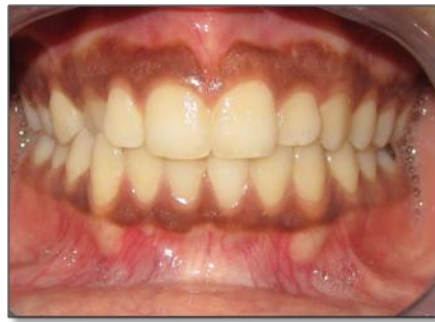### **Case Report**

This case involves an esthetic anterior crown lengthening along with gingival depigmentation that

was completed using diode laser at the same appointment. A 23-year old female patient reported to Department of Periodontology, Manipal College of Dental Sciences, Manipal with the demand for cosmetic correction of “Black Gums” and uneven smile line. (Figures 2, 3). After oral prophylaxis the patient was recalled after 7 days for the gingivectomy and depigmentation procedure.



**Fig 2: Pre-Operative Smile**

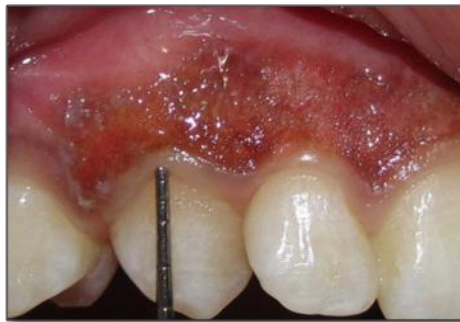

**Fig 3: Pre-Operative Frontal View**

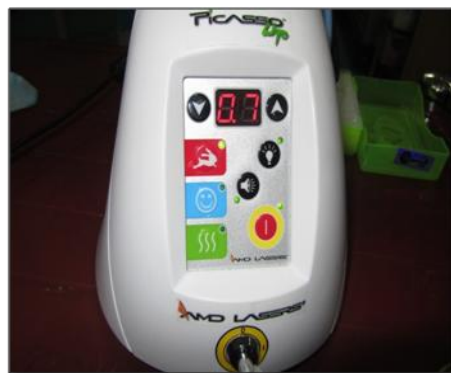### Diode Laser Gingivectomy and Depigmentation Procedure

Under local infiltration careful probing of the sulcus and bone sounding was done (Figure 4) to provide accurate information as to the depth of the gingival sulcus complex, and the amount of free gingiva that is available to be excised. The right canine was only 7 mm in length and right central incisor was smaller than the left (Figure 2). A minimum of 1.0-1.5 mm of

gingival sulcus was retained to avoid inflammation of the tissue and impingement of biologic width. The diode laser was used in contact for these procedures, and as such should be used with an initiated tip. Proper initiation of the tip uses articulating paper at 0.5 continuous wave for 5-8 seconds painting both the tip and the sides of the disposable single use tip. The procedure was performed using the picasso single use disposable tips (Figure 4).



**Fig 4: Crown Lengthening**



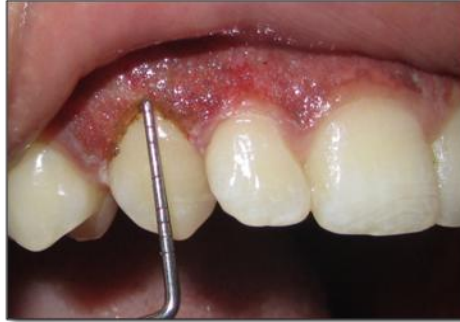**Figure 5: Diode Laser**

The genotype of the tissue is important to consider when determining settings that should be used. The thinner the tissue, the more likely recession can occur

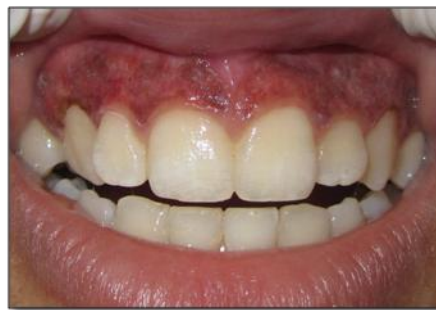if the clinician uses higher settings. Therefore careful evaluation of the laser tissue interaction with magnification is essential to success. The tip of the

laser was held at a 45 degree angle to the tissue, in an external bevel fashion, and gently moved horizontally back and forth in a brush like fashion. Similarly the gingival depigmentation was performed using paint brush like strokes. These gingival recontouring and

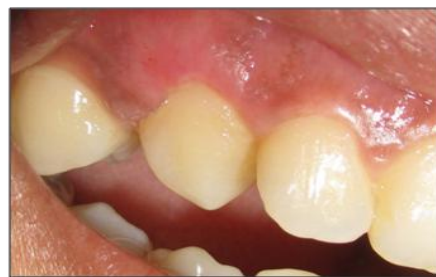depigmentation procedures were completed at low settings of around 0.6-1.5 watts continuous wave (CW) with an initiated tip. A follow-up was done at the end of 1 day. The patient was completely asymptomatic postoperatively (Figure 6-9).



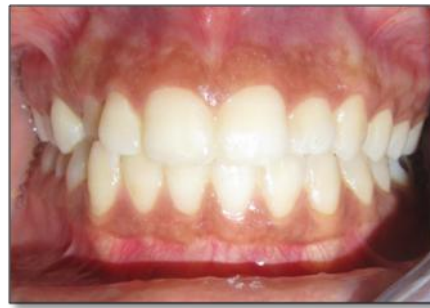**Fig 6: Immediate Post-Operative View**



**Fig 7: Immediate Post - Operative View after Gingivectomy and Depigmentation**



**Fig 8: Post - Operative View 1month**



**Fig 9: Post – Operative After 6 Months**

## Results

There was no postoperative pain, hemorrhage, infection or scarring occurred in any of the sites. The patients were observed at 1 day, 4 days and 1 week after the procedure and the healing was found to be uneventful. The patient's acceptance of the procedure was good and the results were excellent, as perceived by patient. The follow-up period spanned over 6 months. There was slight recurrence of pigmentation observed in 6 months.

## Discussion

Various methods of de-epithelialization of the pigmented areas of the gingiva have been documented, such as scalpel surgery, gingivectomy, gingivectomy with free gingival autografting, cryosurgery, electrosurgery, chemical agents such as 90% phenol and 95% alcohol, abrasion with diamond burs, Nd:YAG laser, semiconductor diode laser and CO<sub>2</sub>. All these methods have their particular advantages and disadvantages. The case reports describe depigmentation technique using 980 nm diode laser surgeries. A one step laser treatment is usually sufficient to eliminate the pigmented areas and does not require any periodontal dressing.<sup>3</sup> This has the advantage of easy handling, short treatment time, hemostasis, decontamination and sterilization effects.<sup>3</sup> But this approach needs expensive and sophisticated equipment that is not available commonly at all places and it makes the treatment very expensive. The diode laser is a solid-state semiconductor laser that typically uses a combination of gallium (Ga), Arsenide (Ar), and other elements, such as Aluminum (Al) and Indium (In), to change electrical energy into light energy dental laser energy has an affinity for different tissue components.<sup>9</sup> The 980 nm diode laser has energy and wavelength characteristics that specially target the soft tissues. It has an affinity for hemoglobin and melanin, therefore

it is more efficient and better equipped to address deeper soft tissue problems. Since, the diode does not interact with dental hard tissues at reduced power settings, the laser is an excellent soft tissue surgical laser, indicated for cutting and coagulating gingiva and oral mucosa, and for soft tissue curettage or sulcular debridement.<sup>10,11</sup> This property can easily be utilized to perform single sitting comfortable gingivectomy and minor gingival soft tissue contouring as performed in above case.

Laser procedures require careful handling of laser tips and tissues. If the tip is dragging then the energy setting should be raised, but if charring or carbonization is occurring then the settings should be lowered. Excessive carbonization of tissue can lead to iatrogenic sequelae including recession, and post operative pain.<sup>12</sup> Minor areas of carbonization can occur even with ideal settings, but these localized areas of charring, can be eliminated by rubbing hydrogen peroxide over the area with a cotton pellet or a microbrush dipped in the 3% hydrogen peroxide solution and scrubbed gently on the area. Since the laser is end cutting, dragging the tip rapidly across the tissue will not ablate the tissue, but either cause the tip to break, or result in bleeding and slow cutting.

## Conclusion

Excessive gingival display and gingival hyperpigmentation are major concerns for a large number of patients. Although several techniques are currently in use, the scalpel technique is still the most widely employed. Lasers and cryosurgery may offer less postoperative pain. Additionally, A surgical soft tissue grafting for depigmentation may ensure less chance for recurrence over a five year follow up. The diode laser is a minimally invasive treatment option for the elimination of unesthetic gingival melanin pigmentation. None of the three patients experienced

any intraoperative or postoperative pain or discomfort. The results in all the three cases were excellent at 3-month follow-up period. There was no evidence of repigmentation of the gingiva resulting in improved esthetics. The external bevel gingivectomy combined with the depigmentation procedure described above offers a practical technique to dramatically improve patient esthetics.

### Reference

1. Cicek Y, Ertas U. The Normal and Pathological Pigmentation of Oral Mucous Membrane: A Review. *J Contemp Dent Pract.* 2003 Aug 15; 4(3): 76-86.
2. Dummett CO, Barends G. Pigmentation of the oral tissues: A review of the literature. *J Periodontol.* 1967; 38: 369-78
3. Dummett CO, Barends G. Oromucosal Pigmentation: an updated literary review. *J Periodontol.* 1971 Nov; 42(11): 726-36.
4. Dummett CO. Oral Tissue Color Changes (I). *Quintessence Int.* 1979 Nov; 10(11): 39-45.
5. Kanakamedala AK, Geetha A, Et Al. Management of Gingival Hyperpigmentation by surgical scalpel technique. *J Clin Diagn Res* 2010 April; 4: 2341-46.
6. Mathews MA. Diode Lasers: A versatile clinical tool (a technical and clinical review). *Intl J Laser Dent* 2011; 1(1): 9-15.
7. Spencer P, Cobb CM, Wieliczka DM, Et Al. Change in temperature of subjacent bone during soft tissue laser ablation. *J Periodontol* 1998; 69: 1278-1282
8. Sarver DM. Principles of cosmetic dentistry in orthodontics: Part 1. Shape and proportionality of Anterior Teeth. *Am J Orthod Dentofacial Orthop.* 2004; 126: 749-53.
9. Doshi Y, Khandge N, Byakod G, Patil P. Management of gingival pigmentation with diode Laser: Is it a predictive tool? *Int J Laser Dent* 2012; 2(1): 29-32.
10. Gupta G. Management of gingival hyperpigmentation by semiconductor diode Laser. *J Cutan Aesthet Surg* 2011 Sep-Dec; 4(3): 208-10.
11. Mathews MA. Diode Lasers: A Versatile Clinical Tool (A Technical and Clinical Review). *Intl J Laser Dent* 2011; 1(1): 9-15.
12. Flax HD. Soft and Hard Tissue Management Using Lasers In Esthetic Restoration. *Dent Clin North Am.* 2011 Apr; 55(2): 383-402.