



## A Study On Clinical, Radiological Outcome Of Acute Dorsolumbar Fractures Treated By Posterior Decompression And Stabilisation And Fusion And Instrumentation At The Fractured Vertebra

<sup>1</sup>Dr. P. Rajeev Kumar, <sup>2</sup>Dr. M. Ganeshkumar, <sup>3</sup>Dr. S. Anbarasan

<sup>1,2</sup>Assistant Professor, <sup>3</sup>Senior Resident,

Department Of Orthopedics,

<sup>2,3</sup>Madurai Medical College

<sup>1</sup>Govt Medical College Hospital Theni

**\*Corresponding Author:**

**Dr. M. Ganeshkumar**

Assistant Professor, Department Of Orthopedics, Madurai Medical College

Type of Publication: Original Research Paper

Conflicts of Interest: Nil

### Abstract

**Background:** The thoracolumbar junction is a unique one because of its anatomy and biomechanical environment. Dorsolumbar spine fractures are one of the most common causes of traumatic paraplegia and paraparesis with or without bladder and bowel involvement. These fractures occur most commonly in a younger individual. 90% of all spinal fractures occur in the thoracic and lumbar spine. Most common presentations of thoracic and lumbar injuries are within the level between T11 and L1.

**Aim & Objective Of The Study:** to study the clinical, radiological outcome of acute dorsolumbar fractures treated by posterior decompression and stabilization and fusion and instrumentation at the fractured vertebra.

**Methodology:** The prospective study was done in patients with Post Traumatic acute dorsolumbar fractures in the Department of Orthopaedics, Madurai Medical College & GRH, Tamil Nadu. Twenty-four patients were treated surgically between June 2021 to December 2021 and followed for a period of 7 months to two years. Anteroposterior and lateral plain X-rays, CT scans, and MRI were taken to identify all injuries and to assess the severity and nature of the injury. The neural canal and pedicle were identified in the CT scan. Soft tissue injuries and cord changes were identified in MRI. The level and type of fractures were classified according to Dennis and McAfee's classification.

**Results:** The commonest mode of injury was fall from height (79%). The other mechanisms are road traffic accidents (16%) and wall collapse (5%). On admission, five (20.8%) patients were Grade A, ten (41.6%) - Grade C, nine patients (37.5%) in Grade E. Regarding the level of vertebral fracture, D11 (3 patients-12.5%), D12 (9 patients -37.5%) and L1(14 patients – 58.3%) were the involved. The commonest type of fracture was Burst fracture in nineteen patients (79.1%). Three patients (12.5%) had Fracture dislocation six (25%) had a Compression fracture and two patients (8%) had flexion distraction fractures. Vertebral body collapse at the time of injury, eleven (45%) had 40-50% body collapse, ten (41%) had 50-60% body collapse, two (8%) had more than 60% body collapse. 9 (36%) patients had associated injuries in which Calcaneal (16%) and tibial pilon (8%), Pubic rami (4%), distal radius (4%); metatarsal (4%) fractures were the commonest associated injuries in our study. No intra-operative complications were observed. Post-operatively, three (12.5%) had sacral bed sores, two (8%) had surgical site wound infection and one (4%) had screw cut out. All three cases of sacral bed sores healed well after flap cover. The infected surgical site was debrided and secondary suturing was done. Post-operatively, the patients were followed in the first, third, sixth month, and one year with the clinical and radiological examination. The longest follow-up was 2 years, shortest 8 months with a mean of 16 months.

Frankel's grade improved to Grade E in 3 patients (21%) and Grade D in 6 patients (43%) from grade C, six months after surgery. The neurological status remained static in five patients (Grade A - five patients)

**Keywords:** Spinal Injuries, Thoracolumbar Trauma, Management

## Introduction

The thoracolumbar junction is a unique one because of its anatomy and biomechanical environment. Dorsolumbar spine fractures are one of the most common causes of traumatic paraplegia and paraparesis with or without bladder and bowel involvement. <sup>[1]</sup>These fractures occur most commonly in a younger individual. 90% of all spinal fractures occur in the thoracic and lumbar spine. The most common presentations of thoracic and lumbar injuries are within the level between T11 and L1. The causes for thoracolumbar fractures are motor vehicle accidents, falls from height, and injuries related to occupation and recreational activities. It has major functional, psychosocial, medical, and financial effects on the injured person, family, and society. The treatment modalities are conservative therapy and surgery. Surgery includes either posterior reduction and instrumentation or anterior decompression and instrumentation. This is one of the controversial areas in modern spine surgery and continues to evolve. <sup>[2]</sup>Early mobilization and rehabilitation is the most important aim of the management. Hippocrates was the first one to treat spinal fractures in the form of bed rest, postural reduction direct mobilization, ambulatory bracing, and a combination of these. The goal was to mobilize the patient early with or without a brace. Till 1970, Conservative treatment was followed. <sup>[3]</sup>Most of the dorsolumbar fractures are unstable ones. So it needs surgical spinal stabilization to maintain the anatomical reduction and stability and to promote the early bony fusion, early mobilization. So nowadays most dorsolumbar fractures are treated surgically to allow rapid mobilization and protection against neurological injury when the patient is ambulant and to prevent the complications of bed rest. <sup>[4]</sup>The treatment of patients with mild deformity and incomplete neurological deficit is either conservative or surgical management is controversial. During the past 20 years, the field of spine surgery has seen a dramatic increase in operative management. The development of biomechanically

sound instrumentation to provide stable internal fixation has changed the concepts of patient management. <sup>[5]</sup>

## Methodology

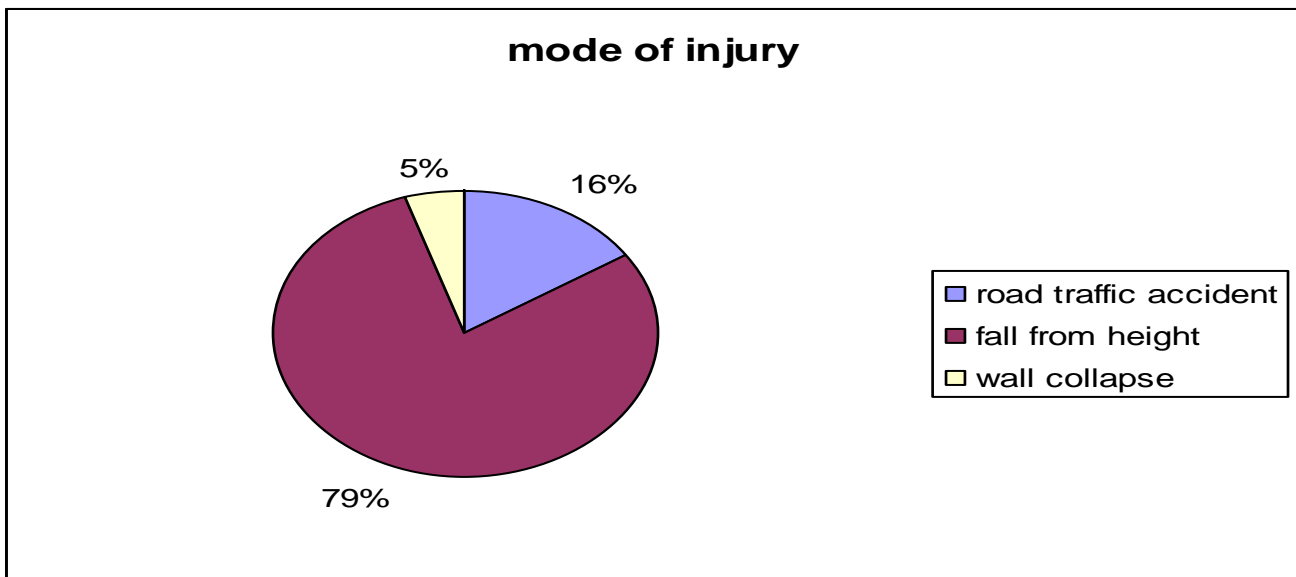
The prospective study was done in patients with Post Traumatic acute dorsolumbar fractures in the Department of Orthopaedics, Madurai Medical College & GRH, Tamil Nadu. Twenty-four patients were treated surgically between June 2021 to December 2021 and followed for a period of 7 months to two years. Anteroposterior and lateral plain X-rays, CT scans, and MRI were taken to identify all injuries and to assess the severity and nature of the injury. The neural canal and pedicle were identified in the CT scan. Soft tissue injuries and cord changes were identified in MRI. The level and type of fractures were classified according to Dennis and McAfee's classification. Inclusion criteria were; Dorsolumbar fractures with neurological deficit. Dorsolumbar fractures without neurological deficit with TLISS of more than five. All unstable Dorso lumbar burst fractures. Age: 18 to 60 years. Presentation less than three weeks after the time of the injury. Exclusion criteria included: 1. Unfit for anesthesia with Comorbid condition. 2. Fracture old >1 month. 3. Vaccora score <3 (i.e. stable fracture) 4. An open vertebral fracture. 5. Pathological fracture. The skeletal system was examined to rule out associated injuries. The patient's spine was examined for any swelling, contusion tenderness hematoma, gibbous, or step off. Full neurological examination (sensation, motor, anal tone) was done and documented repeatedly. Protection of the spinal column was given immediately. Daily neurological examination was done. Pattern & level of neurological injury were identified and noted & Cord injury was graded by Frankel's Classification. Antero posterior and lateral plain X-rays, CT scans, and MRI were taken to identify all injuries and to assess the severity and nature of the injury. The neural canal and pedicle were identified in the CT scan. Soft tissue injuries

and cord changes were identified in MRI. The level and type of fractures were classified according to Dennis and McAfee's classification. The aim of treatment was to mobilize the patient early and to obtain a stable spinal column and maximum neurological function. Factors that were taken into the account are. Stability of the Spinal injury.cord injury(Complete or Incomplete Cord Injury) Patient factors (age, comorbid, associated injuries). Then Vaccaro score was given to all the patients, according to that treatment was given. The indications for surgical intervention were: Vaccaro scores more than five.2. Vertebral body collapse > 50%.3. Canal compression by bony fragment > 50%.4. Cobbs angle of > 30 degrees, and 5. Injury to all three vertebral columns. If Patients had one of these indications were treated surgically. The patient and his/her relatives were explained in detail about the nature of the injury, the severity of the injury, the possible outcomes of non-surgical/surgical management, and the importance of rehabilitation. The patients under the effect of general anesthesia

were positioned on the fracture table and anteroposterior & lateral X – rays were obtained to determine the direction of the pedicles, endplates, and disc spaces. All patients were undergone. Posterior stabilization and decompression are by transpedicular screw and rod instrumentation 2. Additional transpedicular screw instrumentation at fracture site.3. In all patients, the vertebral body is reconstructed by posterior lateral or transpedicular decompression4. Facetal joint fusion is done with bone grafting. 5. It is done by short-segment instrumentation based on fracture morphology. The aim was to decompress the cord, restore the normal sagittal and coronal spinal alignment, and achieve stable internal fixation. Post-operative intravenous antibiotics were given for five days, sutures removed on the 12<sup>th</sup> post-op day and patients discharged after thorough education regarding back care, bladder care, and the rehabilitation protocol. Patients were followed up in the next month with a complete neurological examination (Frankel's grading) and radiograph

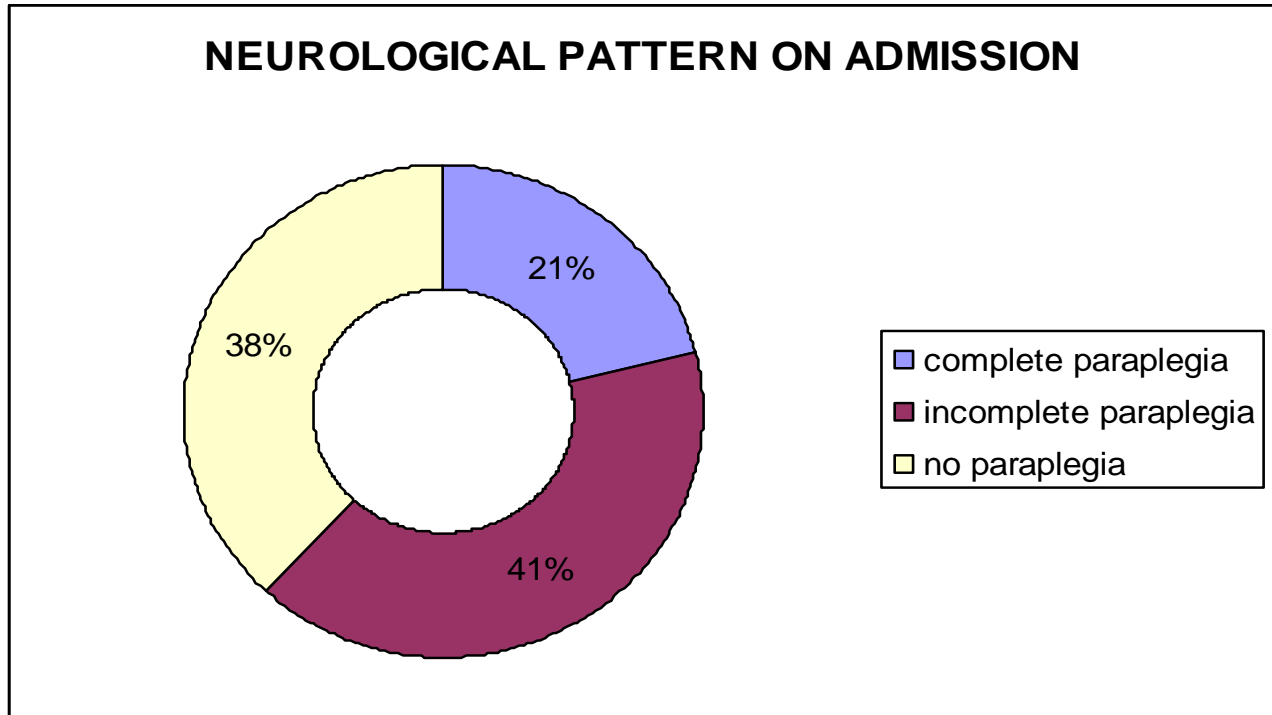
### Observation & Results

Graph :1 Mode Of Injury



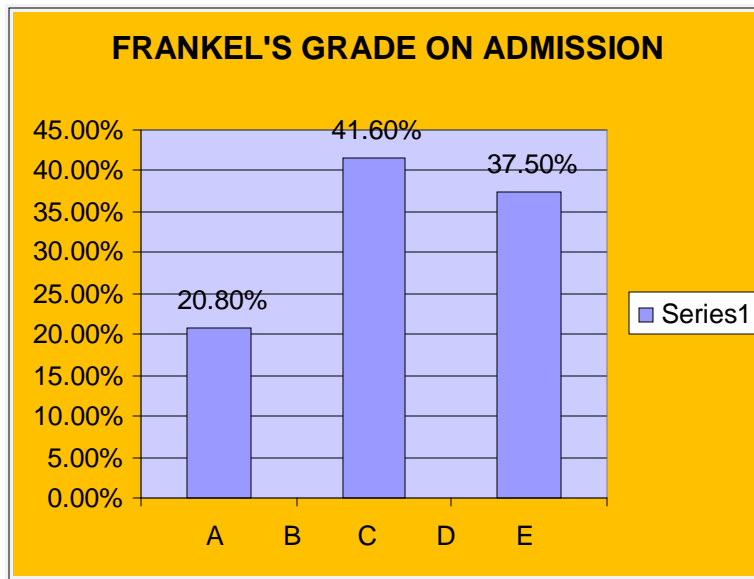
Graph :1 The commonest mode of injury was fall from height (79%). The other mechanisms are road traffic accidents (16%) and wall collapse (5%).

Graph:2 Neurological Pattern On Admission



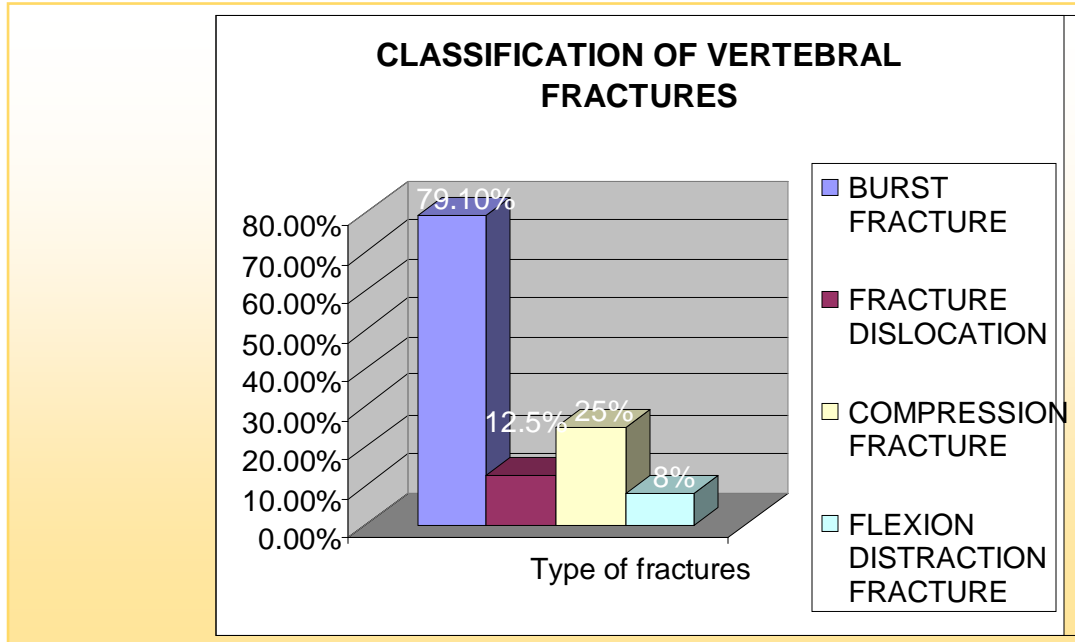
Graph:2 Of the 24 patients admitted, five (20.8%) had complete paraplegia ten (41.6%) had incomplete paraplegia and nine patients (37.5%) without no deficit.

Graph:3 franklinsgradescale



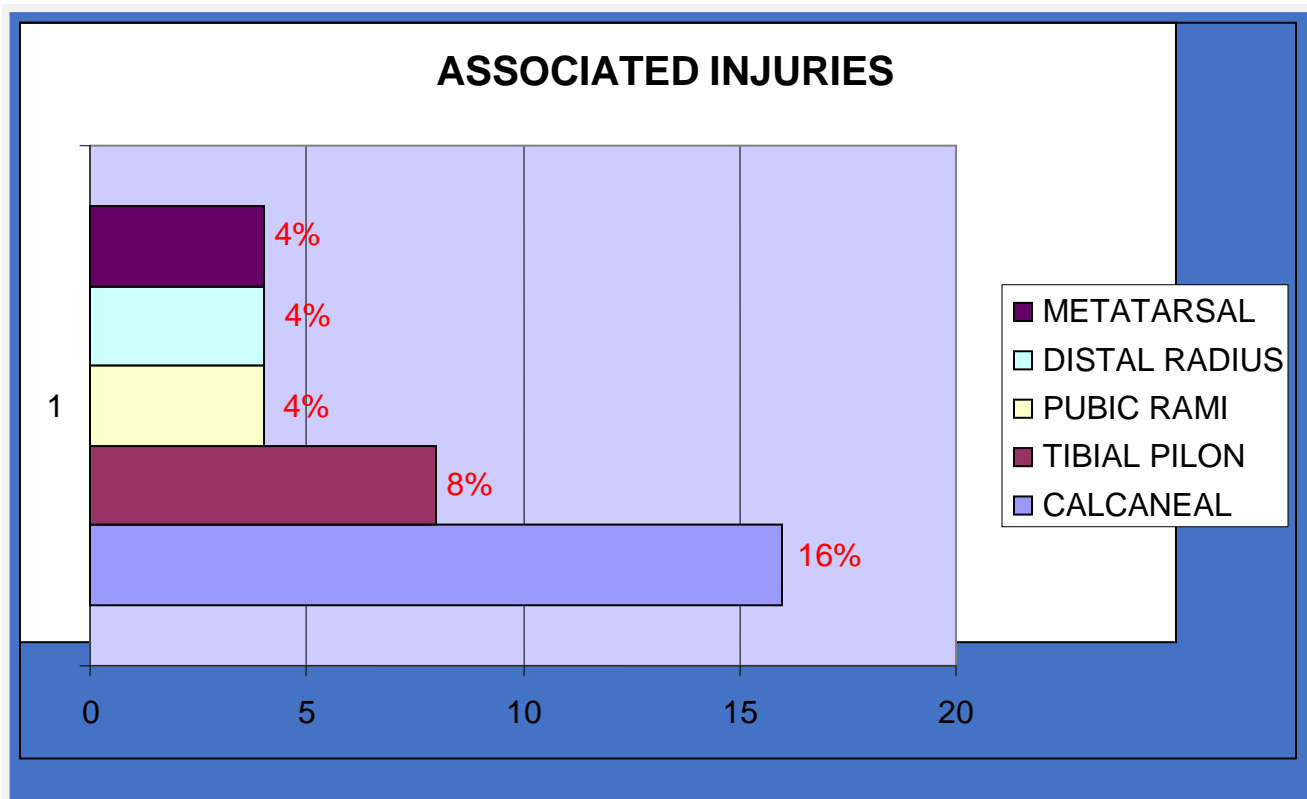
Graph :3 On admission, five (20.8%) patients were Grade A, ten (41.6%) - Grade C, nine patients (37.5%) in Grade E. Regarding the level of vertebral fracture , D11 (3 patients-12.5%) ,D12 (9 patients -37.5%) and L1(14 patients – 58.3%) were the involved.

**Graph:4 Classification Of Vertebral Fractures**



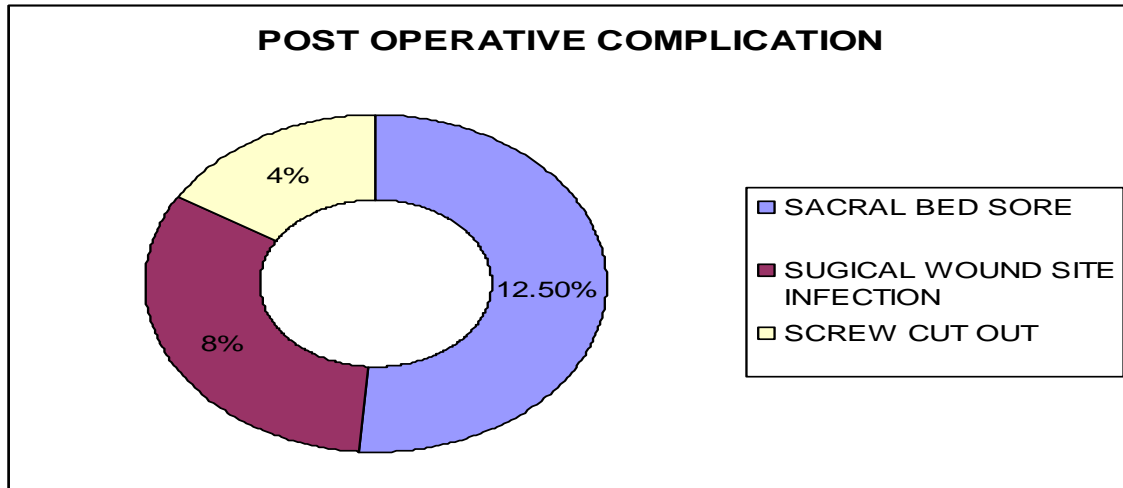
graph: 4 The commonest type of fracture was Burst fracture in nineteen patients (79.1%). Three patients (12.5%) had Fracture dislocation and six (25%) had Compression fracture and two patients (8%) flexion-distraction fractures. Vertebral body collapse at the time of injury, eleven (45%) had 40-50% body collapse, ten (41%) had 50-60% body collapse, two (8%) had more than 60% body collapse.

**Graph:5 Associated Injury**



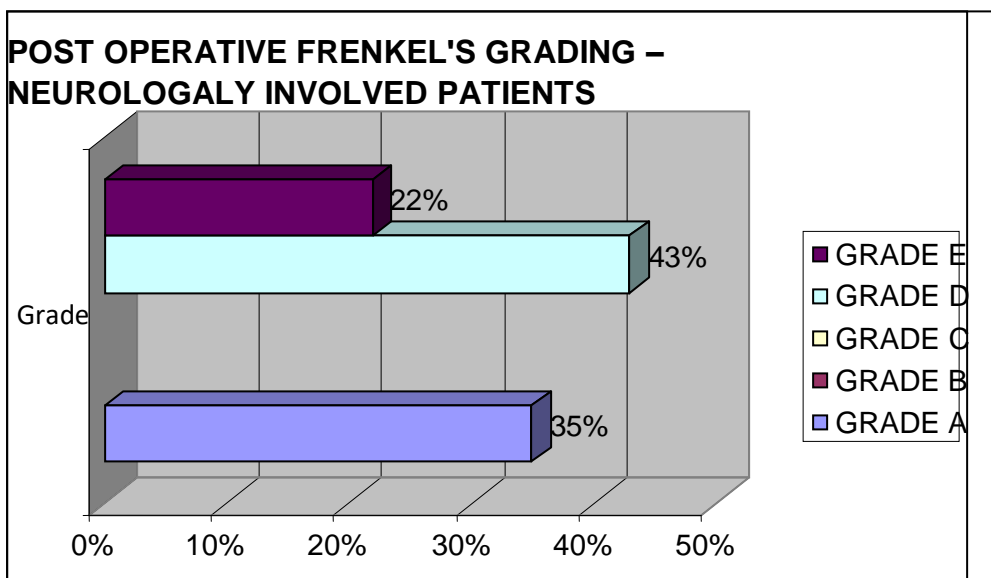
Graph:5 9 (36%) patients had associated injuries in which Calcaneal (16%) and tibial pilon (8%), Pubic rami (4%), distal radius (4%); metatarsal (4%) fractures were the commonest associated injuries in our study. Of the twenty-four patients, nine (37.5%) were operated on within the first week of injury, eight patients (33.3%) in the second week, and seven (29.1%) in the third week.

**Graph:6 Post-Operative Complications**



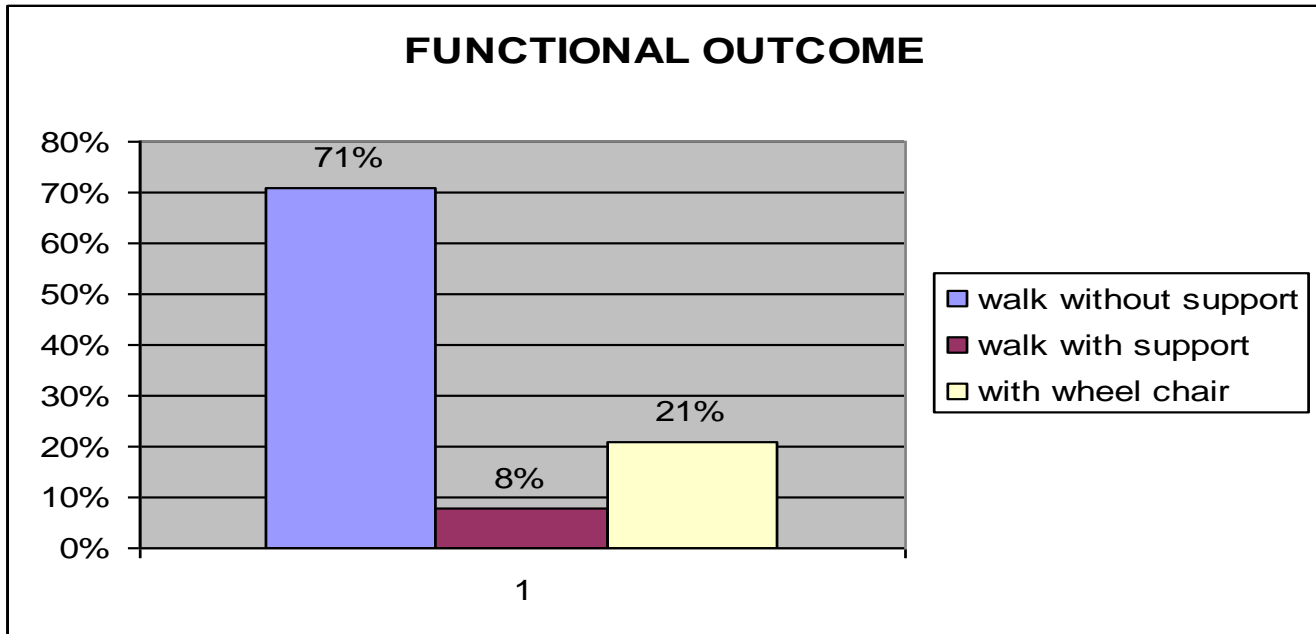
Graph:6 No intra-operative complications were observed. Post-operatively, three (12.5%) had sacral bedsores, two (8%) had surgical site wound infection and one (4%) had screw cut out. All three cases of sacral bed sores healed well after flap cover. The infected surgical site was debrided and secondary suturing was done. Post-operatively, the patients were followed in the first, third, sixth month, and one year with the clinical and radiological examination. The longest follow-up was 2 years, shortest 8 months with a mean of 16 months. Frankel's grade improved to Grade E in 3 patients (21%) and Grade D in 6 patients (43%) from grade C, six months after surgery. The neurological status remained static in five patients (Grade A - five patients)

**Graph:7 Post-Operative Frenkles Grading Neurologically Involved Patients**



Graph:7 Postoperatively at the end of 16 months vertebral body height was maintained up to 95% body height in seven (29%) patients, 90% in seven patients (29%) 85% body height in six (25%), 80% body height in 4(16%)

Graph:8 Functional Outcome



Graph:8 Bladder and bowel sensation improved in ten patients (41%) after eight months, and the five (20%) patients were trained for self intermittent catheterization and condom drainage. On twelve months follow-up, seventeen (71%) were able to walk independently and two (8%) with aids. five (21%) were able to ambulate using a wheelchair.

**Discussion**

The transitional anatomy of the dorsolumbar spine renders it uniquely vulnerable to the high-energy deceleration trauma associated with falls and motor-vehicle accidents. The primary objectives of initial evaluation and diagnosis include characterization of the injury and identification of any neurological deficit. The goals of the treatment are to obtain a stable spine and adequate canal clearance, leading to earlier mobilization of the patient. [6] Spinal injuries are more common in younger individuals. They are most commonly caused by falls from height and motor vehicle accidents (Carpenter et al 1991). But in adolescents, it is more common in sports activities [7] In our study the commonest mode of injury was fall from height(79%). The other mechanisms are road traffic accidents and wall collapse. Males have a four-fold increased risk than females in most of the studies. We also encountered a more number of male patients (83.3%) with a mean age group of 34.75. In 5 % to 20% of patients with spinal injuries have contiguous & noncontiguous spinal injuries. Failure to detect these injuries can lead to delayed instability

and neurological deterioration. In our study, seven patients(29%) associated with contiguous vertebral fractures were encountered. Depending on the type of DL spine injury, associated spinal and nonspinal injuries occur in up to 50% of patients (Cotler et al 1986, Court-Brown 1988). Intra thoracic injuries occur in about 20% of patients while intra abdominal injuries occur in 10% of associated skeletal injuries occur in up to 20% of patients. Calcaneal fractures are the commonest one. Calcaneal (16%), tibial pilon (8%), and Pubic rami (4%) fractures were the commonest associated injuries in our study. [8] The treatment of thoracolumbar fractures with cord injury remains a controversial issue. McLain studied patients with severe spinal fractures treated with segmental fixation and described its advantages viz. immediate mobilization of patients with less dependence on bracing, the distribution of corrective forces over multiple levels, and the reduction of the likelihood of implant failure. [9] Indication for surgical intervention is the presence of progressive neurological deterioration with spinal cord compression. when adequate canal clearance is given in this injury, neurological recovery is good. Of the

twenty-four patients in our series, nine (37.5%) were operated on within the first week of injury, eight patients (33.3%) in the second week, and seven (29.1%) in the third week. <sup>[10]</sup>Excellent spinal canal decompression can be achieved by either a posterolateral, transpedicular, or anterior. In our study, the spine was exposed through only the Posterior approach. The majority of the cases (60%) have undergone postero-lateral, transpedicular decompression. Many authors felt that in the absence of neurological deficit but with canal, compromise is not an indication for surgery because the canal will remodel later. <sup>[11]</sup>A long segment fusion can be done in the upper and middle thoracic spine. After all, it does not affect mobility very much. But thoracolumbar is functionally very important. Preservation of mobility in these segments is important for manual workers. Transpedicular screw rod system is currently the standard in segmental fixation of thoracolumbar spine. Posterior surgery with a short segment stabilization allows early mobilization. Posterior surgery corrects deformity but post-operative vertebral collapse is common, which leads to post-surgical kyphosis. Post-surgical kyphosis is a clinical and radiological condition, which results following a failure after operative stabilization. It can be mild, moderate, or very severe depending on the degree of body collapse. <sup>[12]</sup>Sometimes they can present with neurological symptoms. Most commonly they will present with pain. To prevent these complications instrumentation at the fractured vertebra should be done. In our series, all patients underwent posterior short segment fixation and instrumentation at the fractured vertebra. Which will give additional stability and maintain the reduction, it prevents post-operative body collapse and instrumentation failure. In our study, we were not encountering postsurgical kyphosis for any cases and we maintained vertebral body height post-operatively even after 18 months of follow-up what we achieved on the table. <sup>[13]</sup>In our series, we instrumented at the fractured vertebra on one side of the pedicle and another side we went transpedicular approach for anterior body reconstruction and bone grafting. In our study with short-segment pedicle screw-based fixation with instrumentation at fractured vertebra has been done for all patients. While out of bed the patient must wear a brace, for 6-8 weeks until the fusion consolidates <sup>[14]</sup>We used whatever part is

nibbled from the posterior arch of the autologous iliac crest graft to reconstruct the spinal column with excellent results. Post-operative Frankel's grade improved to Grade E in three patients and Grade D in six patients from grade C, six months after surgery which was consistent with most of the major studies. <sup>[15]</sup>

## Conclusion

Our study demonstrates the advantages of early surgical stabilization of unstable thoracolumbar fractures with spinal cord injuries in terms of improved fracture reduction, restoration or preservation of neurological function, achievement of the pain-free fracture site, early mobilization, and thereby fewer complications associated with prolonged bed rest. Instrumentation at the fractured vertebra will prevent the postoperative vertebral collapse and prevent postoperative late kyphosis and instrument failure.

## References

1. Kewalramani LS, Taylor RG. Multiple Non-Contiguous Injuries to the Spine. *Acta Orthop Scand* 1976;47:52-8.
2. Henderson RL, Reid DC, Saboe LA. Multiple Noncontiguous Spine Fractures. *Spine* 1991;16:128-31.
3. Saboe LA, Reid DC, Davis LA, Warren SA, Grace MG. Spine Trauma and Associated Injuries. *J Trauma* 1991;31:43-8.
4. Holdsworth F. Fractures, Dislocations, and Fracture-Dislocations of the Spine. *J Bone Joint Surg Am* 1970;52:1534-51.
5. Denis F. Spinal Instability As Defined by the Three-Column Spine Concept in Acute Spinal Trauma. *Clin Orthop* 1984;189:65-76.
6. Denis F. The Three Column Spine and Its Significance in the Classification of Acute Thoracolumbar Spinal Injuries. *Spine* 1983;8:817-31.
7. Gertzbein SD. Spine Update. Classification of Thoracic and Lumbar Fractures. *Spine* 1994;19:626-8.
8. Magerl F, Aebi M, Gertzbein SD, Harms J, Nazarian S. A Comprehensive Classification of Thoracic and Lumbar Injuries. *Eur Spine J* 1994;3:184-201.
9. Panjabi MM, Oxland TR, Kifune M, Arand M, Wen L, Chen A. Validity of the Three-Column



- Theory of Thoracolumbar Fractures. A Biomechanic Investigation. *Spine* 1995;20:1122-7.
10. James KS, Wenger KH, Schlegel JD, Dunn HK. Biomechanical Evaluation of the Stability of Thoracolumbar Burst Fractures. *Spine* 1994;19:1731-40.
  11. Haheer TR, Bergman M, O'Brien M, Felmly WT, Choueka J, Welin D, et al. The Effect of the Three Columns of the Spine on the Instantaneous Axis of Rotation in Flexion and Extension. *Spine* 1991;16:S312-8.
  12. McAfee PC, Yuan HA, Lasda NA. The Unstable Burst Fracture. *Spine* 1982;7:365-73.
  13. Ballock RT, Mackersie R, Abitbol JJ, Cervilla V, Resnick D, Garfin SR. Can Burst Fractures Be Predicted From Plain Radiographs? *J Bone Joint Surg Br* 1992;74:147-50.
  14. McCormack T, Karaikovic E, Gaines RW. The Load Sharing Classification of Spine Fractures. *Spine* 1994;19:1741-4.
  15. Parker JW, Lane JR, Karaikovic EE, Gaines RW. Successful Short-Segment Instrumentation and Fusion for Thoracolumbar Spine Fractures: a Consecutive 4 1/2-Year Series. *Spine* 2000;25:1157-70.