



A Rare Case Of Internal Hernia Presenting As A Obstructed Inguinal Hernia

¹Dr. Dhaval Chaudhari, ²Dr. Krupesh Chaudhari, ³Dr. Chintan Bhimsen, ⁴Dr. Dhaval Vasava,

^{1,2}Senior Resident, ^{3,4}Assistant Professor,

Department of General Surgery ,

Civil Hospital, GMERS Medical College, Rajpipla , Narmada, 393145

***Corresponding Author:**

Dr. Dhaval Chaudhari

Senior Resident, Department of General Surgery ,

Civil Hospital, GMERS Medical College, Rajpipla , Narmada, 393145

Type of Publication: Case Report

Conflicts of Interest: Nil

Abstract

Keywords: NIL

Introduction

Internal hernias have an overall incidence of less than 1% , they constitute up to 5.8% of small bowel obstruction . if it left untreated have been reported to an overall mortality exceeding 50% if strangulation is present . It caused by 2 ways , one Developmental Defects and second Acquired .

There are three general mechanisms whereby developmental abnormalities result in the formation of internal hernias: 1) Abnormal retroperitoneal fixation of the mesentery resulting in anomalous positioning of the intestine (e.g. mesocolic or paraduodenal hernia; 2) abnormally large internal foramina or fossae ; 3) incomplete mesenteric surface with the presence of an abnormal opening through which the intestine herniates (e.g. mesenterichenia).

Acquired Internal hernias result from the creation of abnormal mesenteric defects after operative procedures or trauma . The creation of a small space allows the herniation of the small intestine through the mesenteric rent and the development of intestinal obstruction . Treatment of these patients is operative reduction of the hernia and closure of peritoneal defect.

Case Report :-

A 48 year old male patient come to surgical OPD at civil hospital , Rajpipla with complain of : Swelling in right groin region since 1 week

Sever lower abdominal pain since 1 day

Vomiting 3-4 episode (Bilious in nature) – 1 day

Swelling was reducible in nature on onset , which become irreducible since last 1 day , and a/w pain which gradually increase .

Patient had complained of vomiting , not passing stool and flatus since 1 day .

Past History :-

1. Left inguinal hernioplasty – 7 years back
2. chest and abdominal blunt injury – 5 years back , patient manage conservatively .

Radiological Investigation :-

X-RAY Abdomen Standing :- multiple air-fluid level seen , which s/o – small bowel obstruction .

Intra-Operative Findings:-

Open at inguinal region for obstructed inguinal hernia :- Mesenteric ring with small bowel coming out from it as a content present

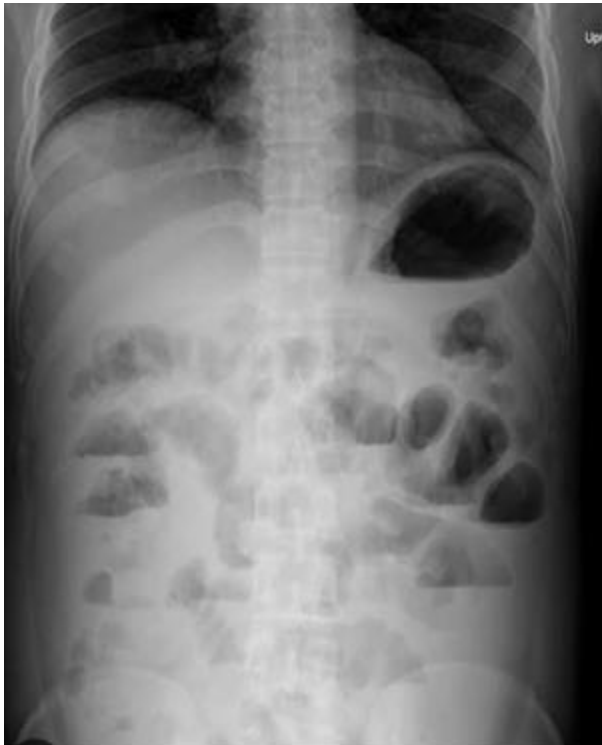Second lower midline laparotomy skin incision kept :- Internal hernia found from mesenteric ring , multiple

small bowel adhesion found and 1-2 stricture at loop found passable ,
proximal bowel loops was dilated & inflamed , distal bowel loops collapsed .

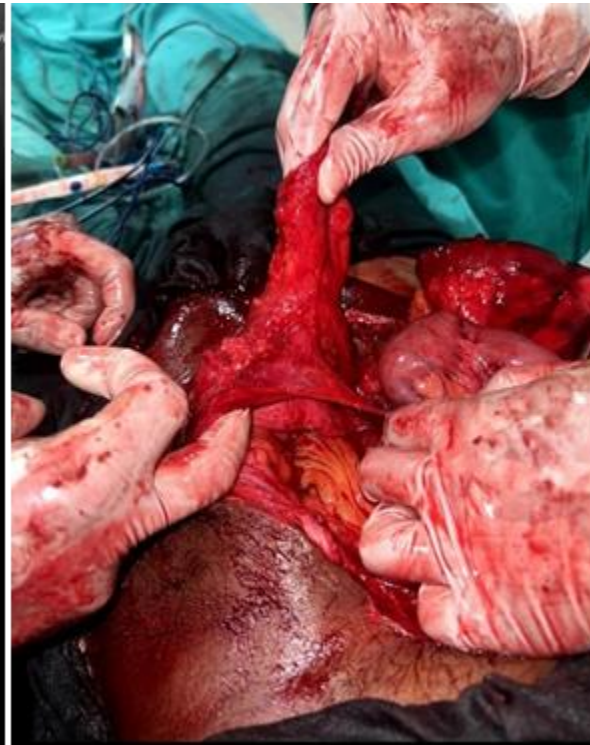Bowel release from obstructed mesenteric ring and mesenteric margin opposed , adhesiolysis done , pre peritoneal meshplasty done .

The post operative course is uneventful , with the patient resuming a normal diet . Regaining normal bowel function at second postop day.

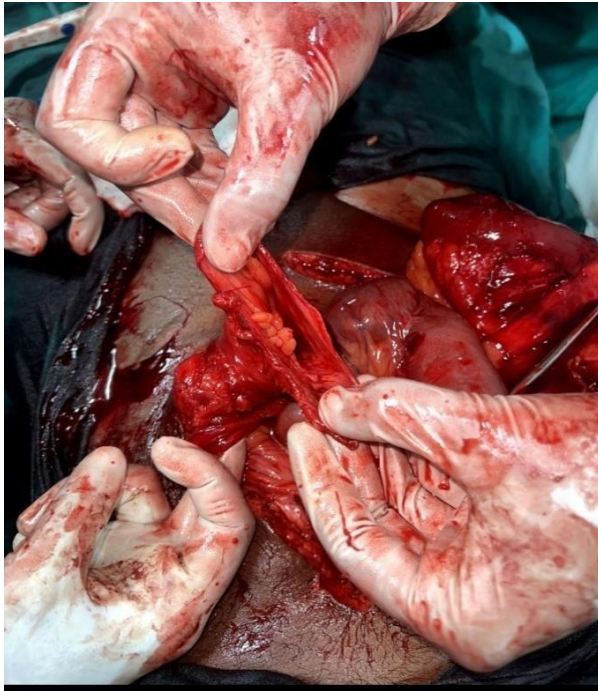
a. X-Ray abdomen standing



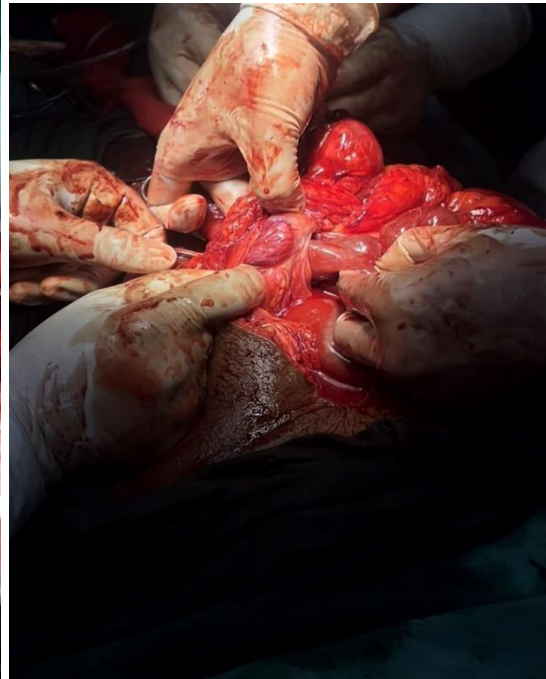
b. Intra-operative pic. s/o mesenteric ring



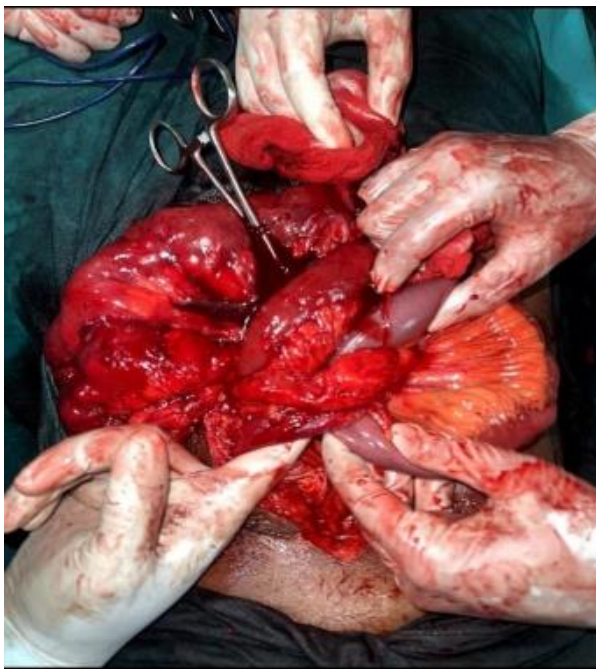
c. Opening of mesenteric ring



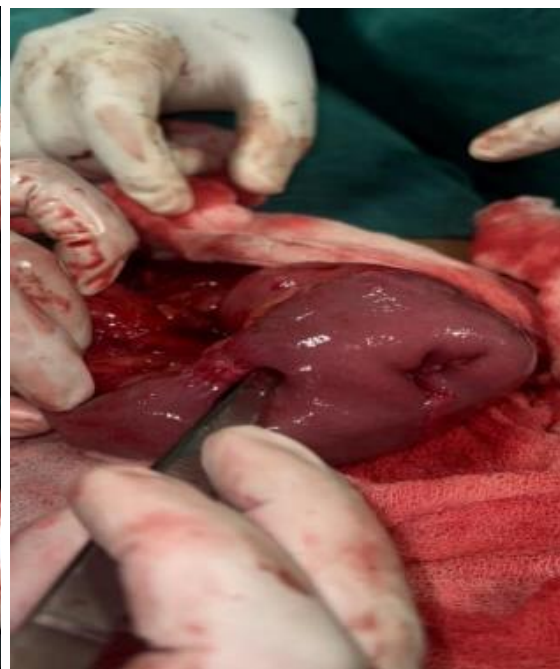d. small bowel passed through ring



e. Small bowel passed through mesenteric ring



f. Multiple small bowel adhesion



Discussion :-

In the adult population , acquired mesenteric defects are more common than congenital defects . they can be caused by surgical interventions (Roux-Y gastric bypass , liver transplantation , small bowel or colon

resection) or abdominal trauma , peritoneal inflammation or ischemic changes . primary or congenital internal hernias in adults are

extremely rare . Congenital internal abdominal hernias (CIAH) are either retroperitoneal or formed from

congenital anomalous openings lacking a true peritoneal sac . retroperitoneal hernias further classified by ghahremani into paraduodenal (30-53 % of CIAH) , pelvic & paravesical henira (6%) , congenital internal hernias can be categorized as transmesenteric (8-10%) , broad ligament (4-7%) or transomental hernias (1-4 %) . Acquired internal hernias in post abdominal trauma (0.2-0.9%) . Patient with a history of blunt abdominal trauma may present with late complication caused by a missed diagnosis of an associated injury , such as small bowel mesenteric injuries .

In this case , patient present with a obstructed right inguinal hernia and signs of small bowel obstruction . He had past history of left inguinal hernioplasty 4 years ago . Also a blunt chest and abdominal trauma 5 years ago which managed conservatively . An abdominal xray suggestive of small bowel obstruction , in such case early operative intervention is essential to decrease morbidity & increase survival .

Conclusion :-

Although internal hernias were previously an uncommon but important cause of intestinal obstruction given the high mortality associated , nevertheless still often underdiagnosed . As illustrated in the present patient , who presented with obstructed inguinal hernia of right side in which small bowel herniation through a mesenteric ring as a content present , with past history of blunt abdominal trauma .

Early surgical intervention is crucial to avert the high risk of associated morbidity and mortality . While conducting emergency surgery for obstructed inguinal hernia with intestinal obstruction , with past history of blunt abdominal trauma , the rare type of internal hernia as seen in our case should be kept in mind .

Refernces :-

1. Ghahremani G. Internal Abdominal Hernias . Surg Clinical North Am 1984;62(2) : 393-406 .
2. Ghahremani G. Abdominal and Pelvic Hernias . In : Textbook of gastrointestinal radiology . Philadelphia Saunders ; 2000 p. 1993-2009 . M. Gore , Richard Levine , Ed.
3. Bharatam KK , Kaliyappa C, Reddy RR , Right sided transmesenteric hernia : a rare cause of acute abdomen in adults . Int J Surg case rep 2014;5:1154-7 .
4. Sabiston Textbook of Surgery 21st Edition , Ch. 44 p. 1097 .
5. Sabiston Textbook of Surgery 21st Edition , Benjamin K. Poulou , Alfredo Maximiliano Carbonell and Michael J. Rosen Ch.45 p. 1105-1133 .
6. Martin L. C. , Merkle E. M. Thompson W. M. Review of internal hernias : radiographic and clinical findings . American journal of Roentgenology . 2006;186(3):703-717 .
7. Lassandro F., Iasiello F., Pizza N. L., et al. Abdominal hernias. Radiographics .2005;25(4):997-1015