(International Print/Online Journal)

SJIF IMPACT FACTOR: 5.565
PUBMED-National Library of Medicine ID-101739732

ISSN (Print): 2209-2870
ISSN (Online): 2209-2862

International Journal of Medical Science and Current Research (IJMSCR)
Available online at: www.ijmscr.com
Volume 4, Issue 6, Page No: 210-214
November-December2021

IJMSCR

Asymptomatic Intracranial Arteriovenous Malformation with Large Intranidal Aneurysm and Micro-Aneurysms

Bhavini Gupta
(Department of Radiology, Dr. D.Y. Patil Medical College, Nerul, Navi Mumbai); Sarfaraz Shaikh(Department of Radiology, Dr. D.Y. Patil Medical College, Nerul, Navi Mumbai)

***Corresponding Author:**
Bhavini Gupta
(Department of Radiology, Dr. D.Y. Patil Medical College, Nerul, Navi Mumbai); Sarfaraz Shaikh(Department of Radiology, Dr. D.Y. Patil Medical College, Nerul, Navi Mumbai)

Type of Publication: Original Research Paper
Conflicts of Interest: Nil

Abstract

The presence of intranidal and extranidal aneurysms with intracranial arteriovenous malformations is quite rare but associated with an extremely high incidence of intracranial haemorrhage. The diagnosis can be made on MRI, using T2* imaging sequences, time-of-flight angiography sequences paired with venograms. Accurate diagnosis is crucial for further management through endovascular surgery and embolization of the feeding arteries. Confirmation of the diagnosis is done using digital subtraction angiography (DSA).Invasive methods of evaluation (DSA) become crucial once the aneurysm bleeds, to pin-point location of bleeds.

Keywords: Intracranial arteriovenous malformation, intranidal aneurysm, microaneurysms, asymptomatic, non-invasive diagnosis

Introduction

Concurrent presence of arteriovenous malformation with intranidal aneurysm is rare, with most of them coming with intracranial haemorrhage1. The chances of haemorrhage rise exponentially with the concurrent occurrence of aneurysm1, making the diagnosis through non-invasive methods futile2. Most patients present with haemorrhage, and a patient presenting without one is extremely rare. No study was found in literature. This case was diagnosed on routine scan, before it could bleed.

Case

A 15-year-old girl presented with intermittent headache associated with a few episodes of dizziness, for a year. No other co-morbidities were present. Eyesight was checked with 6/6 (right) and 6/12 (left) vision. Given the frequency of headaches, a routine magnetic resonance imaging (MRI) of Brain was recommended.

Imaging showed a tightly packed bunch of flow voids are noted without normal intervening brain parenchyma in the parafalcine region. Prominent arterial feeder was noted arising from the left A2/A3 segment of left anterior cerebral artery. Venogram showed multiple dilated, tortuous cortical veins, continuing from the flow voids and draining into a significantly dilated inferior sagittal sinus.

These dilated veins showed almost immediate filling after arterial filling. There was also a large intra-nidal aneurysm, with thrombosed component within. The shaggy walls of the aneurysm had multiple outpouching suggestive of micro-aneurysms.

Significant mass effect from the aneurysm and dilated vessels could be appreciated, in the form of subfalcine herniation, transtentorial herniation and rotation of brainstem, compression of anterior horn of left lateral ventricle.

There was no evidence of intracranial haemorrhage in the current scan. Spetzler-Martin grading system was used. Patient was immediately taken up for surgery, and embolization was performed. She experienced an immediate relief in her headaches after the procedure. No known complications or haemorrhages occurred in the posterior surgical period.

Discussion

Haemorrhage is a serious complication of intracranial arteriovenous. 2.7-16% cases are associated with intranidal aneurysms[1], accentuating the high incidence of intracranial bleeds several folds, and introducing new diagnostic dilemmas. Once it bleeds, it is extremely difficult to pin-point the source of bleeding using non-invasive techniques like computed tomography (CT) or MRI[2]. An escalation of annual risk of 7% for intracranial haemorrhage in unruptured concurrent aneurysms (intranidal or extranidal) are noted, in contrast to the annual risk of 1.7% in isolated arteriovenous malformations.[3]

Vessels involved in arteriovenous malformations are devoid of elastic components, making them more prone to bleed[4], or may represent underlying vascular anomaly, hemodynamic alteration, vasoactive stimuli or vascular remodelling. Digital subtraction angiography (DSA) is used for confirmation of diagnosis in ruptured arteriovenous malformations and for locating the source of the bleeding vessel. Treatment options include particulate or liquid embolization for achieving thrombosis, and are beneficial in patients undergoing surgical excision or radiation therapy[5].

References:

1. Deruty, R. et al. "Association Of Cerebral Arteriovenous Malformation And Cerebral Aneurysm. Diagnosis And Management". Acta Neurochirurgica, vol 107, no. 3-4, 1990, pp. 133-139. Springer Science And Business Media LLC, doi:10.1007/bf01405792.
2. Behari, Sanjay et al. "The “Focus On Aneurysm” Principle: Classification And Surgical Principles Of Management Of Concurrent Arterial Aneurysm With Arteriovenous Malformation Causing Intracranial Hemorrhage". Asian Journal Of Neurosurgery, vol 11, no. 3, 2016, p. 240. Medknow, doi:10.4103/1793-5482.145340.
3. Brown, Robert D. et al. "Unruptured Intracranial Aneurysms And Arteriovenous Malformations: Frequency Of Intracranial Hemorrhage And Relationship Of Lesions". Journal Of Neurosurgery, vol 73, no. 6, 1990, pp. 859-863. Journal Of Neurosurgery Publishing Group (JNSPG), doi:10.3171/jns.1990.73.6.0859.
4. Marks, M P et al. "Hemorrhage In Intracerebral Arteriovenous Malformations: Angiographic Determinants.". Radiology, vol 176, no. 3, 1990, pp. 807-813. Radiological Society Of North America (RSNA), doi:10.1148/radiology.176.3.2389040.
5. Marks, M P et al. "Intranidal Aneurysms In Cerebral Arteriovenous Malformations: Evaluation And Endovascular Treatment.". Radiology, vol 183, no. 2, 1992, pp. 355-360. Radiological Society Of North America (RSNA), doi:10.1148/radiology.183.2.1561335.

Figure Legends

Figure 1; T2W images: Multiple, dilated and tortuous, tightly packed bunch of flow voids with flow-related loss of signal, in the left parafalcine region. These flow voids are hypointense on T1W and T2W images. The arterial feeders are seen communicating (supplying) the well-defined lesion in the left fronto-parietal region with significant adjacent oedema. The lesion appears hypointense to isointense with a shaggy hypointense rim, and layering within (suggestive of continued supply). Mass effect is seen as subfalcine herniation, midline shift, compression of lateral ventricles, and thinning of overlying calvaria.

Volume 4, Issue 6; November-December 2021; Page No 210-214

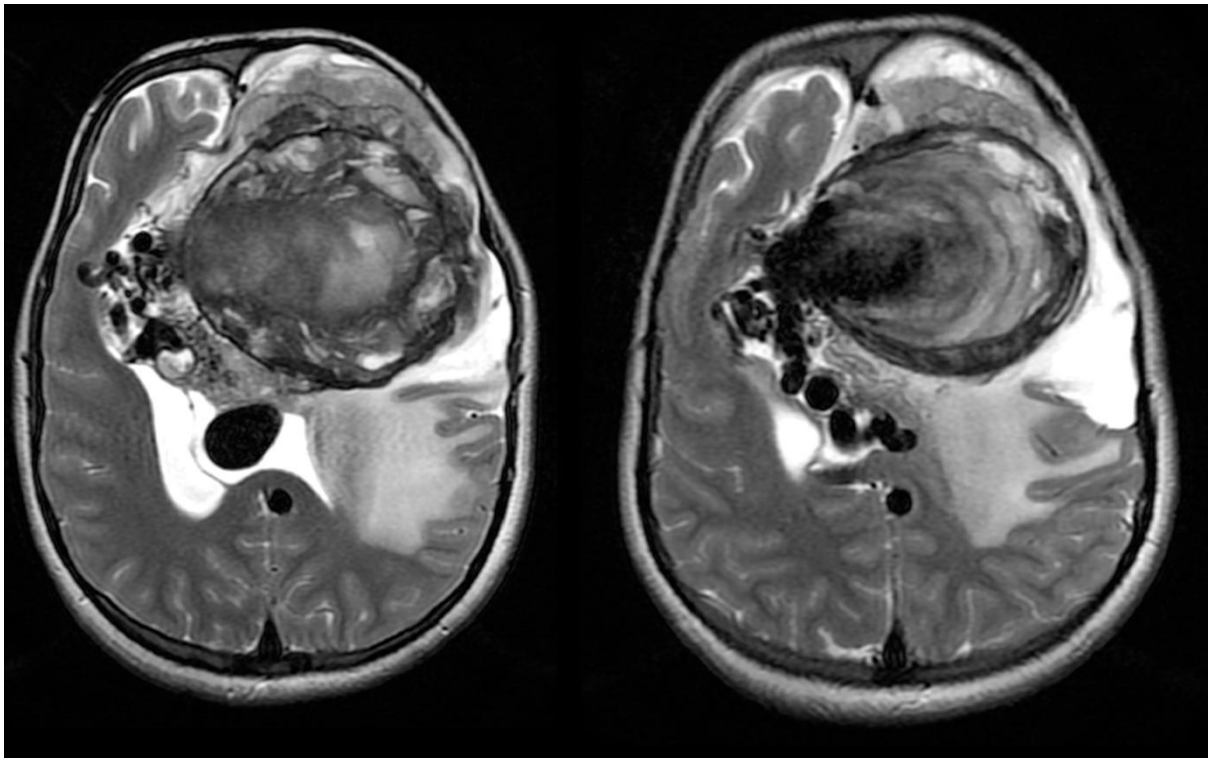

Figure 2; T2* images (SWI): A large well-defined, spherical lesion / area of mixed signal intensity, hypointense to isointense with a few hyperintense areas within and hypointense rim on T2W images was present in the left fronto-parietal region, showing areas of blooming on T2* sequences, suggestive of thrombosed component. This lesion showed communication with the A2 segment of the left anterior cerebral artery, with filling in of contrast, on contrast study. The anterior wall of the lesion demonstrated thick peripheral enhancement with multiple outpouchings, representing microaneurysms.

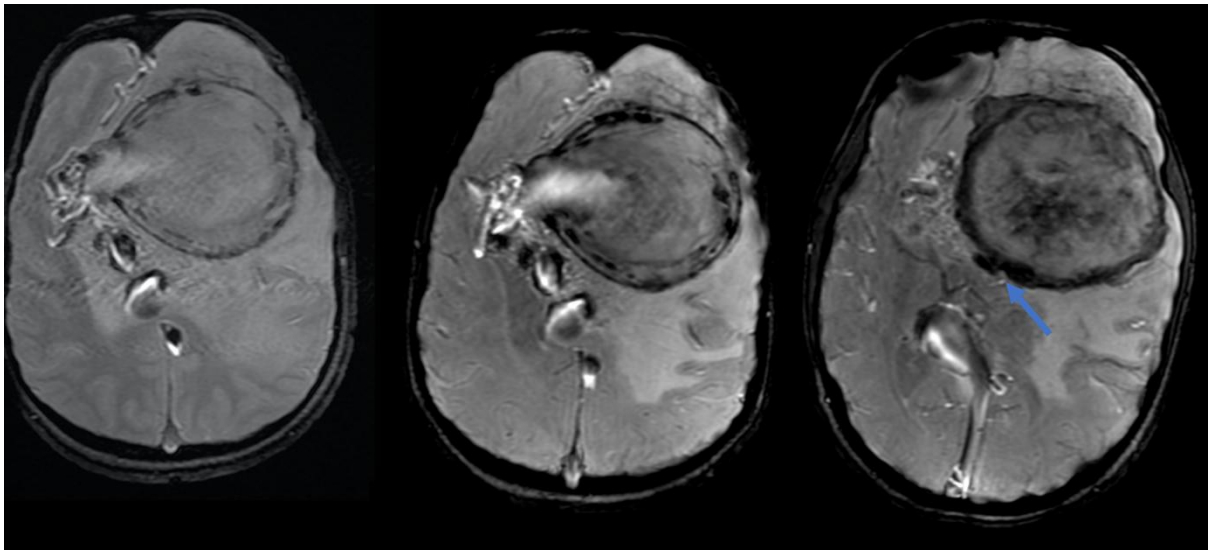

Volume 4, Issue 6; November-December 2021; Page No 210-214

Figure 3; posterior-contrast T1W images: Significant enhancement proving presence of arterial feeders, with simultaneous fill-in of venous channels with arterial filling. There is also sequential fill in of the lesion on posterior contrast study.

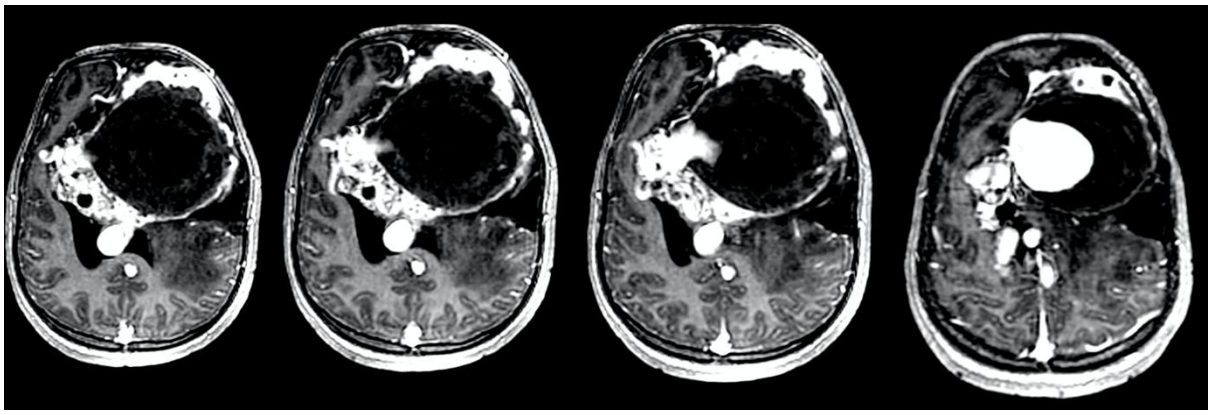

Figure 4; brain venogram: Multiple dilated venous channels (vertical arrow), draining into the inferior sagittal sinus (horizontal arrow), which is significantly dilated. Dilated veins showed almost immediate filling after arterial filling.

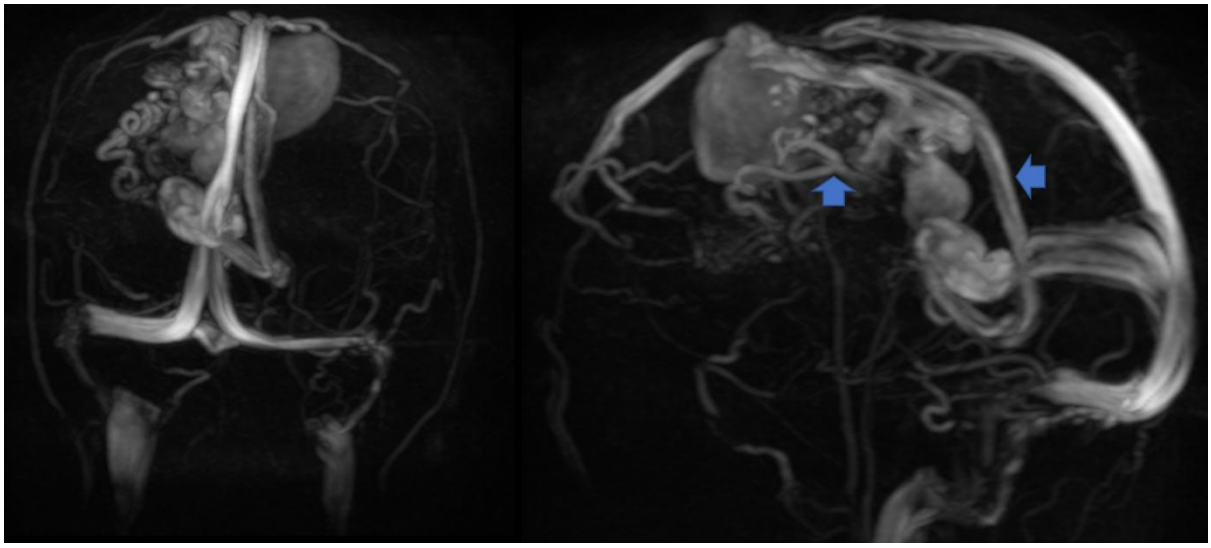

Figure 5; angiogram: Multiple, dilated, tortuous, intracranial arteries with the left anterior cerebral artery seen communicating with the large aneurysm on the left (arrow).

Volume 4, Issue 6; November-December 2021; Page No 210-214

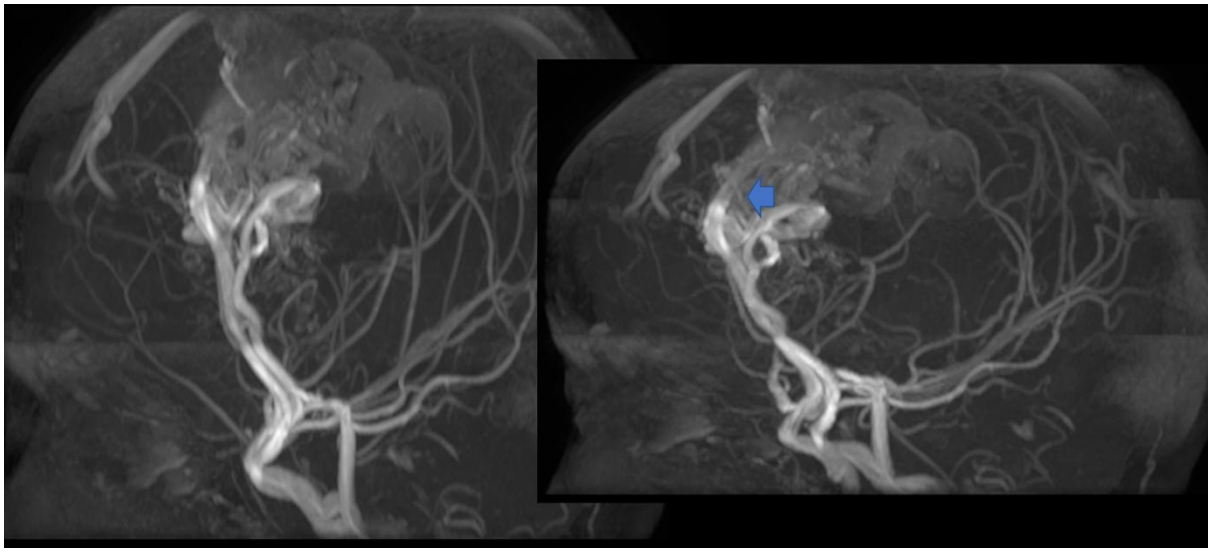

Volume 4, Issue 6; November-December 2021; Page No 210-214