(International Print/Online Journal)

SJIF IMPACT FACTOR: 5.565
PUBMED-National Library of Medicine ID-101739732

ISSN (Print): 2209-2870
ISSN (Online): 2209-2862

International Journal of Medical Science and Current Research (IJMSCR)
Available online at: www.ijmscr.com
Volume3, Issue 5, Page No: 332-337
September-October 2020

Clinico-Histological Spectrum of Endometriosis: A 5-Years Study at a Tertiary Care Centre

[1]Dr. Suwarna B Patil, [2]Dr. Bhupendra V Patil, [3]Dr. Sushma S Deshmukh,
***[4]Dr. Swarada V Kangate, [5]Dr. Pradeep S Umap**
[1]Associate Professor, [2, 3, 4]Assistant Professor, [5]Professor and Head
[1, 4, 5](MD in Pathology), Department of Pathology, Government Medical College, Akola
[2,3]MD in OBGY, Department of OBGY, Government Medical College, Akola

***Corresponding Author:**
Dr. Swarada V Kangate
Assistant Professor, Department of Pathology, Government Medical College, Akola

Type of Publication: Original Research Paper
Conflicts of Interest: Nil

ABSTRACT

Introduction: Endometriosis is defined as the presence of endometrium in an abnormal or ectopic location. Histologically, it is the presence of endometrial-like tissue or glands outside the uterine cavity. It is a gynecological disorder dependent on hormones observed most commonly in women of reproductive age. Depending on the involved site, women can present with various symptoms including bowel obstruction, melena, hematuria, dysuria, dyspnea, and swelling in soft tissues. From the histopathological point of view, three commonly recognized types are: peritoneal, endometriotic cyst, and deep infiltrative lesions. The **aim** of the present study was to study the incidence of endometriosis at different sites, its clinical co-relation with histopathological presentation. **Material and Methods**: The present study was a retrospective cross-sectional study, carried out at Tertiary Care Referral Hospital, in Departments of Pathology and Obstretics and Gynaecology. **Results:** Total of 61 cases were included in the present study. Most common age group was found to be 20 to 30 years (77.1%), followed by 30 to 40 years (19.6%). Most common presenting symptom was dysmenorrhea, followed by meno-metrorrhagia. Maximum cases were of abdominal wall endometriosis (49.1%), among which 22 females (36%) had a scar mark of previous LSCS. Least commonly, endometriosis was found in uterine cervix (3.3%). **Conclusion:** Endometriosis is a benign, complex disorder involving young, reproductive age patients and is characterized by non-specific symptoms and lack of non-invasive diagnostic methods. Endometriosis if not treated properly, can compromise with fertility of the patient, quality of life and health significantly.

Keywords: Endometriosis, Abdominal wall, Dysmenorrhea, Histopathology, Hormones

INTRODUCTION

Endometriosis is defined as the presence of endometrium in an abnormal or ectopic location. Histologically, it is the presence of endometrial-like tissue or glands outside the uterine cavity. It is a gynecological disorder dependent on hormones observed most commonly in women of reproductive age. The ectopic endometrial tissue responds to hormonal stimulation and undergoes cyclic growth and shedding. Without a way to drain, this causes internal accumulation of blood, thus associated with dyspareunia, cyclic menstrual pain, and pelvic pain, having a negative effect on the quality of life of patients. Endometriosis often can present without symptoms, and therefore, is missed frequently as a diagnosis. Its prevalence is between 5% and 10% in premenopausal women and can reach as high as 35%

in women suffering from subfertility, as it can be a major cause of decreased fecundity. The known risk factors for endometriosis include menarche beginning at less than 11 years of age, as well as heavy and prolonged menses.[1] The prevalence is 40-60% among women with dysmenorrhea and it is extremely rare after menopause, because of the estrogen dependence of the ectopic tissue. The relapse of endometriosis during menopause has been correlated with hormonal replacement therapy.[2] The most common sites of pelvic endometriosis are the ovaries, uterine ligaments (largely broad and uterosacral ligaments), pouch of Douglas, and fallopian tubes.[3] Endometriotic implants also have been found in extra-pelvic locations, including the gastrointestinal tract, urinary tract, nasal mucosa, lungs, diaphragm, breast, umbilicus, abdomen (surgical scars), inguinal area, pelvic nerves and pericardium. Gastrointestinal lesions are the most common extragenital manifestation, and the diaphragm is the most frequent extrapelvic site. The catamenial nature of the symptoms (occurring between 24 hours before and 72 hours after the onset of menstruation) may help suggest the diagnosis.[2,4] Depending on the involved site, women can present with various symptoms including bowel obstruction, melena, hematuria, dysuria, dyspnea, and swelling in soft tissues.[5] The goal of management in patients with endometriosis is early diagnosis and focused treatment to prevent disease progression and improve patient's quality of life.[6] It is a polymorphic disease that can manifest as superficial implants on the peritoneal surface; ovarian cysts called endometriomas; or deep lesions that infiltrate the peritoneal surface more than 5 mm, a condition known as deeply infiltrative endometriosis (DIE). DIE is a chronic, progressive, multifocal disease with no known cure or preventive mechanisms.[4] From the histopathological point of view, three commonly recognized types are: peritoneal, endometriotic cyst, and deep infiltrative lesions. Although known for a long time, the etiopathogenesis of endometriosis remains incompletely understood and its diagnosis is often one of exclusion. Numerous theories have been proposed in order to explain the pathogenic mechanisms, which include: retrograde implantation, direct mechanical implantation, coelomic metaplasia, proliferation induction, embryonic remnants, vascular and lymphatic dissemination, and stem cells involvement.[7]

Thus, the present study was carried out with the aim to study the incidence of endometriosis at different sites, its clinical co-relation with histopathological presentation, at a Tertiary Referral Centre.

Materials and Methods: The present study was a retrospective cross-sectional study, carried out at Tertiary Care Referral Hospital. This study was carried in Department of Pathology, over a period of five-years from June 2015 to June 2020. Total of 61 cases were included in the study. All the specimens along with their operative findings were received from Department of Obstetrics and Gynaecology. Clinical history with age, presenting signs & symptoms, radiological and operative findings were studied. Autolyzed samples were excluded.

Gross examination of 10% formalin fixed specimen was done and processed. Sections were stained with Hematoxylin and Eosin (H&E) and studied.[8]

Results: Total of 61 cases were included in the present study.

Among these 61 cases, two females were diagnosed with the abdominal wall endometriosis on cytology, who presented with a lump and were confirmed on histopathological study.

Most common age group was found to be 20 to 30 years (77.1%), followed by 30 to 40 years (19.6%). Only two females were diagnosed in the age group of 40 to 50 years (3.3%) (Fig 1). Minimum age was found to be 20-years with endometriosis at vulva and maximum was 45-years female with ovarian endometriosis, presenting as chocolate cyst.

Volume 3, Issue 5; September-October 2020; Page No.332-337
© 2020 IJMSCR. All Rights Reserved

Figure 1: Age-wise distribution of cases (n=61)

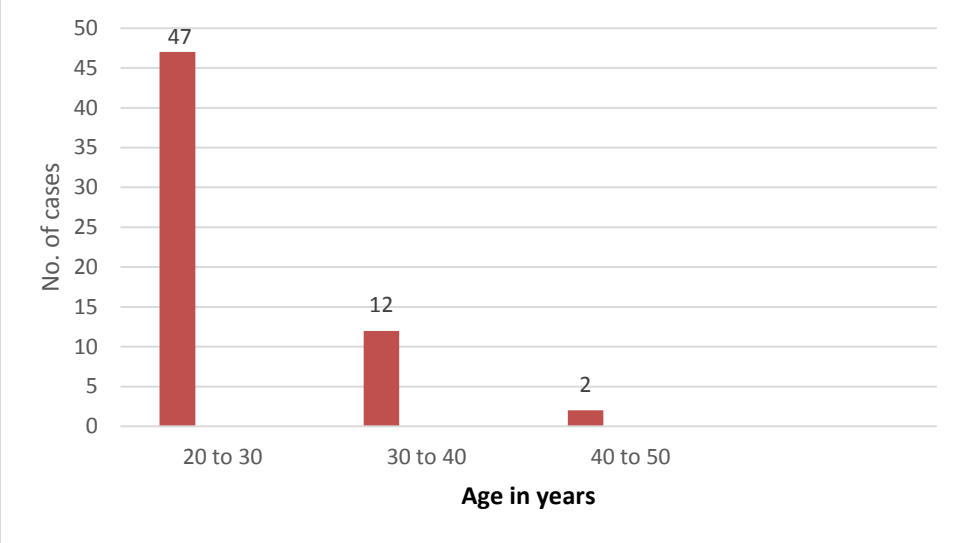

Most common presenting symptom was dysmenorrhea, followed by meno-metrorrhagia. Other associated symptoms were abdominal pain, dyspareunia, infertility and least common was abdominal lump, in the present study (Fig 2).

Figure 2: Distribution of presenting symptoms in the cases (n=61)

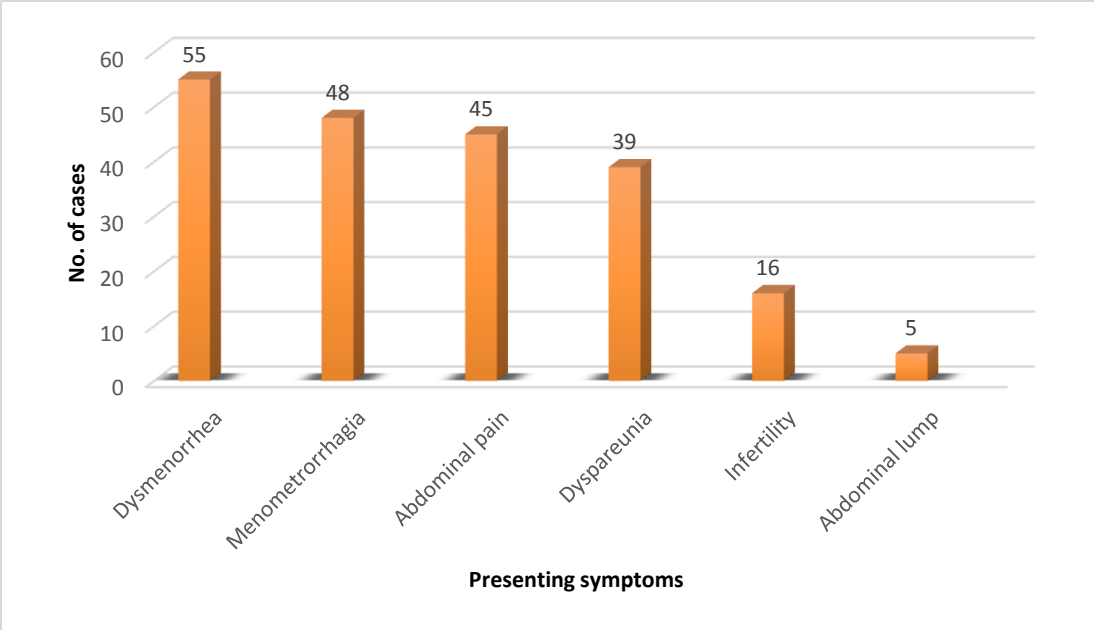

As shown in table 1, maximum cases were of abdominal wall endometriosis (49.1%), among which 22 females (36%) had a scar mark of previous LSCS. Second most common site for endometriosis was fallopian tube (21.3%), followed by ovary (13.1%). We found endometriosis at vulva in 8.1% and at inguinal area in 4.9% cases. Least commonly, endometriosis was found in uterine cervix (3.3%) (Fig 3)

Table 1: Site-wise distribution of the cases (n=61)

Site		No. of cases	Percentage
Abdominal wall (Total 30 cases –	Previous LSCS scar	22	36
	Scar other than LSCS	06	9.8

Volume 3, Issue 5; September-October 2020; Page No.332-337
© 2020 IJMSCR. All Rights Reserved

49.1%)	No scar	02	3.3
Fallopian tube		13	21.3
Ovary		08	13.1
Vulva (Total 05 cases – 8.1%)	Previous Episiotomy scar	04	6.5
	No scar	01	1.6
Inguinal area		03	4.9
Uterine cervix		02	3.3
Total		**61**	**100**

Figure 3: Microphotographs of Endometriosis at different sites

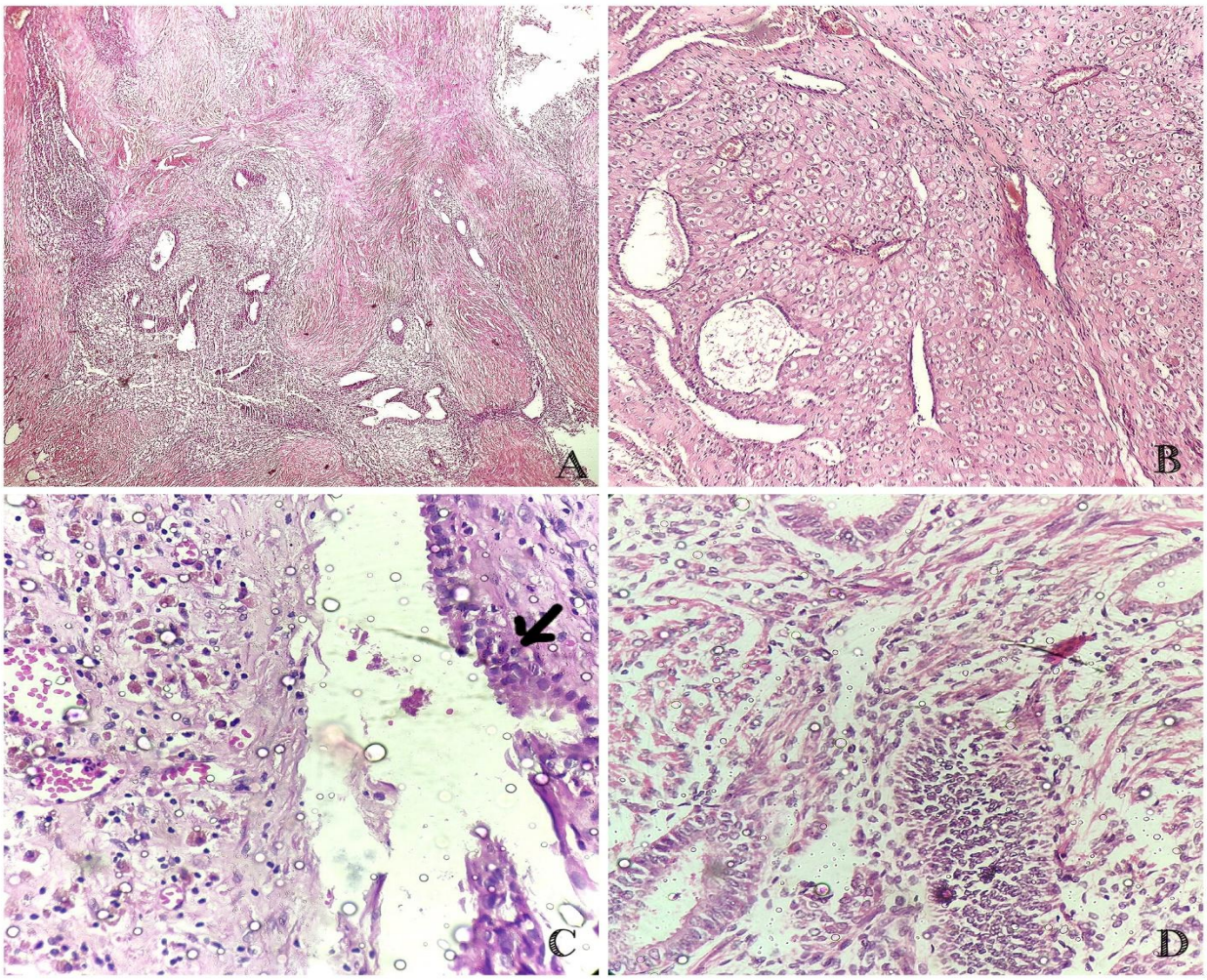

Fig A – Scar Endometriosis showing endometrial glands intermingled with compact stroma

Fig B – Scar Endometriosis with decidual change [luetinization of endometrial stroma]

Fig C – Tubal Endometriosis showing tubal epithelium lining (arrow) with haemorrhage

Fig D – Ovarian Endometriosis showing endometrial glands admixed in ovarian stroma

Volume 3, Issue 5; September-October 2020; Page No.332-337

© 2020 IJMSCR. All Rights Reserved

Discussion: Endometriosis is a benign disease of women characterized by an abnormal growth of endometrial glands and stroma outside the uterine cavity. Women of childbearing age are commonly involved, and this ectopic tissue undergoes normal physiologic response to female reproductive hormones like estrogen and progesterone, which can irritate surrounding tissues.[9] In the present study, females in highly reproductive age of 20 to 30 were most commonly affected.

Most common presenting symptom, in the present study was dysmenorrhea (90.1%), followed by meno-metrorrhagia (78.7%) and abdominal pain (73.8%). Least commonly, females presented with abdominal lump (8.2%). These results co-related with the study done by Ioana Păvăleanu, et al[7] who also found dysmenorrhea as the most common presenting symptom (65.93%).

In present study, maximum cases were of abdominal wall endometriosis (49.1%), among which 22 females (36%) had a scar mark of previous LSCS. Ioana Păvăleanu, et al[7] also reported 13.18% cases of cutaneous endometriosis in post-caesarean scar. The abdominal wall is one of the most frequent extrapelvic locations of endometriosis. Endometriotic implants are usually embedded in the subcutaneous fatty layer and the muscles of the abdominal wall near or at the site of surgical.[10] The most common clinical symptom is a constant focal abdominal pain which is mostly not associated with the menstrual cycle. This pain is frequently atypical, so that it can be easily misdiagnosed. Patients can also feel a palpable mass in the area of surgical section.[2] The condition is frequently associated with a gynecologic procedure such as cesarean section, episiotomy, amniocentesis, laparoscopy, tubal ligation, or hysterectomy, but it can also be found in non-gynecologic surgical scars such as those from appendectomy or umbilical hernioplasty.[4] Present study had six cases (9.8%) of non-gynaecologic surgical scars associated abdominal wall endometriosis. Cesarean scar endometriosis is rare, although it may occur more commonly than believed. It is the most common abdominal wall endometriotic lesion and is located near or at the site of the surgical assessment. It is estimated to occur in 0.03%–1.5% of women after cesarean delivery.[4] This explains the direct mechanical implantation theory of endometriosis. Also, in the present study, two cases (3.3%) cases of abdominal wall endometriosis were noted with no surgical scars.

Endometriosis is a disabling condition which may be ameliorated in its evolution, during pregnancy, and its progression is stopped with onset of menopause. Endometriosis is diagnosed after initiation of menarche, when endometrial cells pass via the fallopian tubes into the peritoneal cavity, leading to the development of viable ectopic implants.[7]

The retrograde mechanical implantation theory (Sampson's theory), is based on the retrograde menstruation mechanism, with reflux of endometrial cells through fallopian tubes to ectopic sites, where the endometrial tissue will attach and then implant. It was proposed for the first time by Sampson, in 1927, and subsequently supported by studies demonstrating retrograde menstruation in women with permeable fallopian tubes.[7] In present study, there were 13 cases of endometriosis in fallopian tube (21.3%), followed by eight cases of ovarian endometriosis (13.1%), supporting reflux theory. Lee HJ[5] study noted ovarian endometriosis as the predominant form (96.4%).

In the present study, five females presenting with dysmenorrhea and dyspareunia, were diagnosed as vulvar endometriosis, and all of them gave the history of vaginal delivery. Four (6.5%) had previous episiotomy scar and one (1.6%) had no scar. Lee HJ[5] also found three cases of vulvar endometriosis.

In the present study, incidence of three cases (4.9%) of inguinal endometriosis is comparable with the study done by Lee HJ[5]. Inguinal endometriosis is a rare condition, accounting for 0.3%–0.6% of patients affected by endometriosis, with fewer than 60 cases reported in the literature.[4] The prevalence of inguinal endometriosis on the right side is 90%–94% as compared to the left side. The asymmetric lymphatic drainage, which favors the right inguinocrural region, might explain this phenomenon. In addition, the endometrial cells remain for a longer time on the right side owing to gravity and to protection of the left ligament by the sigmoid colon. Nevertheless, none of these hypotheses offer adequate explanation for the pathogenesis of inguinal endometriosis.[11]

Ioana Păvăleanu, et al[7] study reported 5.49% of cervical endometriosis. Again favoring the reflux theory, similar two cases (3.3%) of uterine cervical endometriosis, were reported in the present study.

Volume 3, Issue 5; September-October 2020; Page No.332-337
© 2020 IJMSCR. All Rights Reserved

Endometriosis in extra-pelvic sites may result from vascular or lymphatic dissemination of endometrial cells to several gynecologic (vulva, vagina, or cervix) and non-gynecologic sites (bowel, appendix, hernia sacs, lungs, skin, or nerves). Because endometriosis could involve any system of the body, one of the major challenges in diagnosing women with suspected endometriosis is to assess the extent of the disease and its functional consequences for the pelvic or extra-pelvic organs.[5]

Recent molecular studies have been directed towards genetic predisposition, estrogen dependence, progesterone resistance, and inflammation, leading to a current consensus on the association of endometriosis with a chronic inflammatory process induced and/or sustained by the peritoneal microenvironment.[7]

Conclusion: Endometriosis is a benign, complex disorder involving young, reproductive age women. It is characterized by non-specific symptoms and lack of non-invasive diagnostic methods. Endometriosis if not treated properly, can compromise with fertility of the patient, quality of life and health significantly. The catamenial nature of the symptoms can help suggest the diagnosis and guide the clinical investigation. Treatment of endometriosis usually requires a multidisciplinary approach. Surgical excision of all lesions is the best approach for definitive treatment.

Endometriosis-associated lesions underline the influence of common hormonal factors and immune deficiencies in their etiopathogenesis and justify the alternative of hysterectomy as a surgical treatment addressing all these pathological spectra.

Bibliography:

1. Alimi Y, Iwanaga J, Loukas M, et al. (September 25, 2018) The Clinical Anatomy of Endometriosis: A Review. Cureus 10(9): e3361.
2. Machairiotis N, Stylianaki A, Dryllis G, et al. Extrapelvic endometriosis: a rare entity or an under diagnosed condition?. *Diagn Pathol*. 2013;8:194. Published 2013 Dec 2.
3. Klemmt PA, Starzinski-Powitz A: Molecular and cellular pathogenesis of endometriosis. Curr Womens Health Reviews. 2018, 14:106-116.
4. Chamié LP, Ribeiro DMFR, Tiferes DA, Macedo Neto AC, Serafini PC. Atypical Sites of Deeply Infiltrative Endometriosis: Clinical Characteristics and Imaging Findings. *Radiographics*. 2018;38(1):309-328.
5. Lee HJ, Park YM, Jee BC, Kim YB, Suh CS. Various anatomic locations of surgically proven endometriosis: A single-center experience. *Obstet Gynecol Sci*. 2015;58(1):53-58.
6. Casper RF: Introduction: A focus on the medical management of endometriosis . Fertil Steril. 2017, 107:521-522.
7. Ioana Păvăleanu, Raluca Anca Balan, Irina-Draga Căruntu, et al. Clinical-histological correlations in endometriosis. Research and Clinical Medicine, 2018, Volume II, Issue I.
8. Bancroft JD, Gamble M. theory and practice Histological Techniques, 5th ed.Edinburgh: Churchill Livingstone. 2001.
9. Gupta AK, Mann A, Belizon A. Appendicitis Caused by Endometriosis Within the Bowel Wall. *Cureus*. 2020;12(8):e9614.
10. Khamechian T, Alizargar J, Mazoochi T. 5-Year data analysis of patients following abdominal wall endometrioma surgery. BMC Womens Health 2014;14:151. doi:10.1186/s12905 -014-0151-4. Published December 5, 2014.
11. Prabhu R, Krishna S, Shenoy R, Thangavelu S. Endometriosis of extra-pelvic round ligament, a diagnostic dilemma for physicians. BMJ Case Rep 2013;2013:bcr2013200465. doi:10.1136/bcr-2013-200465. Published August 19, 2013.

Volume 3, Issue 5; September-October 2020; Page No.332-337
© 2020 IJMSCR. All Rights Reserved