(International Print/Online Journal)

SJIF IMPACT FACTOR: 4.617
PUBMED-National Library of Medicine ID-101739732

ISSN (Print): 2209-2870
ISSN (Online): 2209-2862

International Journal of Medical Science and Current Research (IJMSCR)
Available online at: www.ijmscr.com
Volume2, Issue 3, Page No: 75-81
May-June 2019

Release of Neglected Case of Extensive Post Chulla Burn Abdominoperineal Contracture - A Rare Case Report and Review of Literature

Sheikh Adil Bashir[1], Bhat A Tanveer[2], Wani A Hafiz[3]
[1] Additional Professor, [2]Senior Resident, [3] Professor and Head
Department of Plastic and Reconstructive Surgery, SKIMS,Soura,Srinagar, India

***Corresponding Author:**

Bhat A Tanveer
Postdoctoral Senior Resident,
Apartment No G9, Block B,Senior Resident Hostel,
SKIMS Soura, Srinagar, J & K, India.PIN 190011

Type of Publication: Case Report
Conflicts of Interest: Nil

ABSTRACT

Post burn contracture (PBC) of trunk, perineum and groin are relatively infrequent, and are disfiguring and functionally restrictive, usually seen in the setting of large surface area burn injuries. We report a neglected case of extensive post flame- burn contracture in a 40 year old unmarried female, involving trunk,groin, perineum and knees. Release of the contracture with split thickness skin grafting was done in two stages under general anesthesia with an intervening period of skin traction. We concluded that even extensive post burn contractures involving groin and perineum can be managed by simple options like skin grafting and if neglected can not only be disfiguring but also crippling and problematic in walking, sitting, squatting, and even sexual intercourse.

Keywords: Chulla burn, contracture, perineum, STSG

INTRODUCTION

Every year there are about 0.7–0.8 million hospital admissions with burns in India[1] as compared to about 13,000 in the UK.[2] This major difference shows the gravity of this problem in India where there are very few hospitals with separate burn units. The groin and perineum are very important sites in the body anatomically and functionally. Both American and European Burn Associations categorize perineal /genital burns as "severe" with a recommendation for transfer to specialized burn care units for management even if the actual surface area involved is very less.[3],[4] The perineum including the groin region constitutes approximately 5% of the total body surface area (TBSA) and is a very important site owing to the presence of the genitalia. Serious coital problems, besides functional limitations, may ensue if burns in these anatomical regions are not managed correctly. Fortunately though, burn contractures here are rare. The perineum usually escapes burn injury due to its deep location between the thighs. Most often, it is the burn contracture of the surrounding area, *i.e.*, the lower part of the abdomen, the inguinal area, and the adjacent thighs that secondarily distorts the perineum, less often it is the perineum that is primarily burnt and can, if not treated appropriately, result in contracture

CASE REPORT

A 40 year old unmarried female from a remote area, accompanied by her brother, presents with ulceration with discharge of duration of 2 months in the genital region. The patient had sustained a major Chulla,a traditional stove, burn in her childhood at an age of 10 years. She was managed by a local physician and the wounds healed by secondary intention resulting in severe post burn functional deformity and disfigurement. On examination there were extensive contractures involving bilateral groins and extending to anterior aspects of abdominal wall and the bilateral

thighs [figure 1],the right nipple was pulled down below the level of umbilicus [figure 1],the perineum was obliterated [figure 2] and the right knee was flexed because of contracture in popliteal fossa [figure 4]. There was an unstable scar with an overlying ulceration in the obliterated perineum [figure 3] which made the patient to seek medical attention. The patient was functionally crippled and had great difficulty in walking, sitting, urination, defecation. The patient had not married because of this problem. The patient insisted treatment for the unstable scar only and was initially reluctant for treatment of the extensive deformity. However on proper counseling she agreed for the release the contractures and skin grafting.[figure 5] Skin grafting was done in two stages [figure 6,7] as patient was put on skin traction for severe soft tissue contracture of right knee after the first setting. However the patient did not cooperate with the skin traction after 4 days and was taken for second setting of skin grafting. Right knee contracture was managed by multiple z-plasties [figure 4]. Skin grafts were harvested from lateral and posterior aspects of bilateral thighs [figure7]. The patient healed well and was discharged after 12 days.

DISCUSSION

Commonly, patients seek consultation for reconstruction of post burn contractures of the hand, neck, and lower limb. Minor perineal burn contractures which can be unsightly are normally ignored by the patients as they are well hidden by clothes. However, these perineal burn contractures can cause a functional disability. The thick scar bands across the symphysis pubis behind the genitals can bind the thighs together, leading to impairment of the movement of the hip joints, especially abduction. Due to this limitation in movement, walking, sitting, urination, defecation, and sexual intercourse become difficult.

The mode of injury in this case was Chulla burn different from the reported modes of burn injury i,e kerosene burns and scald burns [1,2,5-13]. Our state is located in the Himalayan ranges with 60% of the population living in villages surrounded by thick forest. The majority of these villages are located in far flung snow-bound areas with poor road connectivity, leading to unavailability of Liquid Petroleum Gas (LPG) cylinders. Although kerosene pressure stoves are frequently used by villagers or economically poor families for cooking in India, the use of the Chullah is a common practice seen in this state. Due to poor economical status, cold climate, and easy availability of wood, the Chullah is widely used for cooking and heating purposes. People are in the habit of sitting in front of burning wood placed in the Chullah for cooking purposes and warming and this can lead to fall of sparks on the clothes and burn injury primarily in the lower body due to its closeness to the fire. In a study by Jagdeep S Thakur [14] in a state of Himalayan region, perineal burns were found in 6 patients of ,5 females and 1 male, who had suffered burns from burning firewood used in the Chullah. As stated by Ahuja and Bhattacharya,[1] the use of loose clothes during cooking is the major cause for catching the flame in the burn injury.

Extensive raw areas were produced on release of these contractures and can be resurfaced by STSG only [15]. Many authors have reported the successful use of skin grafts to resurface large raw areas after the release of perineal contractures.[14,5,16] .Wani and Rashid as well as Pisarski et al., recommended STSG for perineal contractures of any severity.[16,17] Long-term measures have to be instituted postoperatively to prevent skin graft contraction such as wearing tightly fitting undergarments as reported by Sawhney[5] and Rutan.[18] This long-term measure is the main drawback of this technique but one has to contend with all the problems associated with split thickness skin grafts in the absence of alternatives.

As reported by other authors,[1,19–22] the management of burn patients in the developing world is different from that in the developed world due to lack of education, funds, burns units, and untrained staff. Hence, improvement has to make in these areas, especially in encouraging people to use LPG stoves, as their use not only reduces the chances of these types of accidents but also conserves the environment, a major issue in this decade

CONCLUSIONS

We have reached many conclusions. Perineal and groin contractures may be neglected by the patients especially females, due to shyness and lack of knowledge. Extensive raw areas produced on release of these contractures can be easily resurfaced by STSG-the simplest and most easy treatment option. Educating people for early medical consultation and

Volume 2, Issue 3; May-June 2019; Page No. 75-81
© 2019 IJMSCR. All Rights Reserved

proper postoperative care and rehabilitation can prevent these burn sequelae.

REFERENCES

1. Ahuja RB, Bhattcharyas ABC of burns: Burns in the developing world and burn disasters. BMJ. 2004;329:447–9. [PMC free article] [PubMed] [Google Scholar]
2. Hettiaratchy S, Dziewulski P. ABC of burns: Introduction. BMJ. 2004;328:1366–8. [PMC free article] [PubMed] [Google Scholar]
3. American Burn Association. Advanced Burn Life Support Providers Manual. Chicago, IL: American Burn Association; 2010.
4. European Burns Association. European Practice Guidelines for Burn Care & Guidelines for the Operations of Burn Units; 2002. p. 55-62.
5. Sawhney CP. Management of burn contractures of the perineum. Plast Reconstr Surg. 1983; 72:837–42. [PubMed] [Google Scholar]
6. Balakrishnan C, Imel LL, Bandy AT, Prasad JK. Perineal burns in males secondary to spouse abuse. Burns. 1995; 21:34–5. [PubMed] [Google Scholar]
7. Gupta M, Bansal M, Gupta A, Goil P. The kerosene tradegy of 1994, an unusual epidemic of burns: Epidemiological aspects and management of patients. Burns. 1996;22:3–9. [PubMed] [Google Scholar]
8. Weiler-Mithoff EM, Hassall ME, Burd DA. Burns of the female genitalia and perineum. Burns. 1996;22:390–5. [PubMed] [Google Scholar]
9. Michielsen D, Van Hee R, Neetens C, Lafaire C, Peeters R. Burns to the genitals and the perineum in children. Br J Urol. 1996;78:940–1. [PubMed] [Google Scholar]
10. Michielsen D, Van Hee R, Neetens C, LaFaire C, Peeters R. Burns to the genitalia and the perineum. J Urol. 1998;159:418–9. [PubMed] [Google Scholar]
11. Quayle KS, Wick NA, Gnauck KA, Schootman M, Jaffe DM. Description of Missouri children who suffer burn injuries. Inj Prev. 2000;6:255–8. [PMC free article] [PubMed] [Google Scholar]
12. Kumar P, Chirayil PT, Chittoria R. Ten years epidiomological study of paediatric burns in Manipal, India. Burns. 2000;26:261–4. [PubMed] [Google Scholar]
13. Mukerji G, Chamania S, Patidar GP, Gupta S. Epidemiology of pediatric burns in Indore, India. Burns. 2001;27:33–8. [PubMed] [Google Scholar]
14. Jagdeep S Thakur,C.G.S Chauhan et al. Perineal burn contractures; An experience in tertiary hospital of a Himalayan state.2008:41:2:190-194
15. Klein MB. 2015 Reconstructive burn surgery. In: Neligan PC, editor. Plastic Surgery. 3rd ed., vol. 4. Philadelphia: Saunders Elsevier; 2012. [Chapter 22].
16. Wani S, Raashid H. Outcome of split thickness skin grafting and multiple Z-plasties in post-burn contractures of groin and perineum: A 15-year experience. Plast Surg Int 2014;2014. Article ID 358526.
17. Pisarski GP, Greenhalgh DG, Warden GD. The management of perineal contractures in children with burns. J Burn Care Rehabil 1994;15:256-9
18. Rutan RL. Management of perineal and genital burns. J ET Nurs. 1993;20:169–76. [PubMed] [Google Scholar]
19. Davies JW. The problem of burns in India. Burns. 1990;16:S1–14. [PubMed] [Google Scholar]
20. Sawhney CP, Ahuja RB, Goel A. Burns in India: Epidemiology and problems in management. Indian J Burns. 1993;1:1–4. [Google Scholar]
21. Ahuja RB. Managing burns in India: Focusing on newer strategies. Indian J Burns. 1995;3:1–7. [Google Scholar]
22. Ahuja RB, Bhattacharya S. An analysis of 11,196 burn admissions and evaluation of conservative management techniques. Burns. 2002;28:555–61. [PubMed] [Google Scholar].

Volume 2, Issue 3; May-June 2019; Page No. 75-81
© 2019 IJMSCR. All Rights Reserved

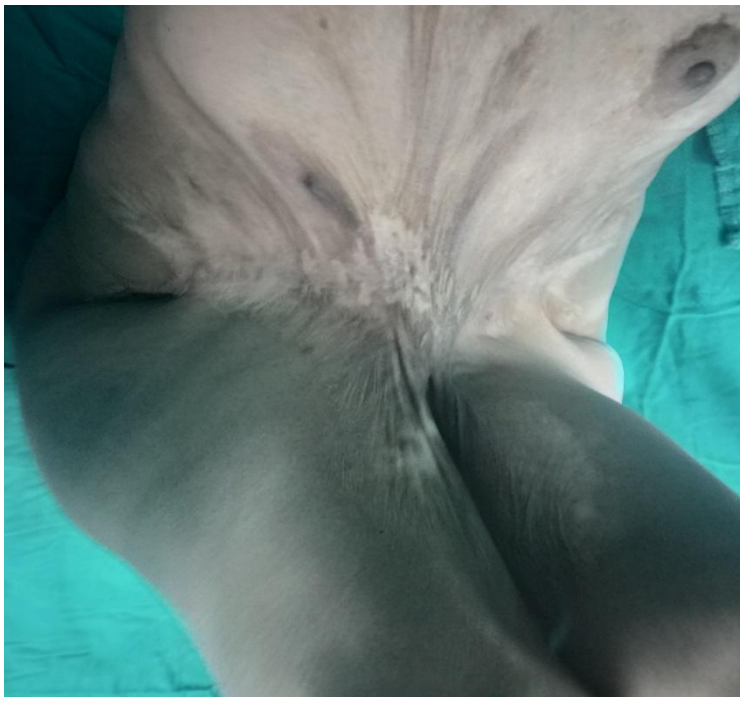

Figure 1: Showing extensive contracture between the anterior abdominal wall and B/L thighs with pulled down right nipple

Figure 2: Showing perineum obliteration- Grishkevich type 2 perineal contracture extending to B/L Knees

Volume 2, Issue 3; May-June 2019; Page No. 75-81
© 2019 IJMSCR. All Rights Reserved

Figure 3: Showing abdominoperineal contracture with unstable scar

Figure 4: Showing marking of multiple z-plasties for contracture of right knee extending to thigh

Volume 2, Issue 3; May-June 2019; Page No. 75-81
© 2019 IJMSCR. All Rights Reserved

Figure 5: Showing release of abdominoperineal contracture with extensive raw area.

Figure 6: Showing stage I of grafting of abdomen and left thig

Figure 7: Showing stage II of grafting of whole raw area with in-situ dressing for the donor site of bilateral thighs

Volume 2, Issue 3; May-June 2019; Page No. 75-81
© 2019 IJMSCR. All Rights Reserved

Figure 8: Showing a traditional chulla used for cooking purposes in rural areas.

Volume 2, Issue 3; May-June 2019; Page No. 75-81
© 2019 IJMSCR. All Rights Reserved