



Role of magnetic resonance imaging in evaluation of carcinoma cervix

Dr Darshan A. V.¹, Dr. Anil Kumar Sakalecha^{*2}, Dr. N. Rachegowda³

Postgraduate, Professor, , Professor and Head

Department of Radiodiagnosis, SDUMC, Tamaka, Kolar

***Corresponding Author:**

Dr. Anil Kumar Sakalecha

Professor, Department of Radiodiagnosis

Type of Publication: Original Research Paper

Conflicts of Interest: Nil

ABSTRACT

Background: Carcinoma cervix is the second most common cancer in women in the developing countries with incidence of about 12%. Accurate pretreatment staging is important for treatment. MRI plays an important role in staging of carcinoma cervix.

Aims and objectives: 1. To document morphological changes in histopathologically diagnosed carcinoma cervix with regional lymph node involvement by MRI. 2. To stage carcinoma cervix by MRI under FIGO guidelines. 3. To compare MRI FIGO staging with clinical FIGO staging in carcinoma cervix.

Materials and methods: This descriptive observational study was carried out over a period of 18 months from January 2017 to June 2018 in 103 patients with histopathologically proved carcinoma cervix who underwent MRI of pelvis.

Results: Majority of patients in our study was mostly concentrated in the middle age group (80%). Most of the patients (n=70; 67%) had parity of 1-3 in our study. 72 (73%) out of 103 patients were postmenopausal. Most common clinical presentation in our study was discharge per vagina (n=93; 90%) followed by post-menopausal bleeding (n=67; 65%). 98 (95.2%) patients in our study were diagnosed with squamous cell carcinoma. On clinical staging, most of the patient were equally staged as IIB (n=47, 45.6%) and IIIB (n=45; 43.6%) followed by IVA (n=5; 4.8 %). On MRI, majority of the patients were staged under stage IIB (47 patients) and stage IVA (35 patients). MRI staging after clinical staging have redistributed the cases among IIB and IIIB. On comparing clinical and MRI staging, it was noted that less than half (n=49) of the cases were staged correctly.

Conclusion: MRI is the preferred imaging technique for tumor detection and invasion evaluation in advanced stage disease. A combined imaging and histopathological approach is warranted in the management of carcinoma cervix. MRI has been proposed as better alternative for initial screening of cervical cancer instead of cystoscopy and proctoscopy.

Keywords: NIL

INTRODUCTION

Carcinoma cervix is the second most common cancer in women in India with an incidence of 22.9% and contributing to 20.7% of all cancer-related deaths in women. It is also notorious for being the second most common cancer to affect the overall population with an incidence of 12.1% and accounting for up to 10% of all cancer-related deaths (men and women combined) . The choice of treatment for carcinoma cervix is completely dependent on its staging and hence an accurate pretreatment staging is important .

The International federation of gynecology and obstetrics (FIGO) staging is widely used for treatment planning and is based on findings at

clinical examination. However there are significant inaccuracies in the clinical FIGO staging system, with an error of 24%–39% in gynecologic examinations. Metastasis to local, regional, pelvic or paraaortic lymph nodes cannot be assessed by clinical examination and also the tumor volume and its extension to the bladder and or rectum is difficult to define, which are critically important for treatment planning .

Magnetic resonance imaging (MRI) has an excellent soft tissue characterization, thereby permitting identification of stromal and parametrial invasion and hence it has an important role in staging of carcinoma

cervix . In Indian rural setup, there is an increasing trend in incidence of carcinoma cervix . The study purpose is to evaluate the role of MRI for accurate pretreatment staging in carcinoma cervix in this rural setup.

AIMS AND OBJECTIVES

The aims and objectives of the study are:

1. To document morphological changes in histopathologically diagnosed carcinoma cervix with regional lymph node involvement by MRI.
2. To stage carcinoma cervix by MRI under FIGO guidelines.
3. To compare MRI FIGO staging with clinical FIGO staging in carcinoma cervix.

MATERIALS AND METHODS

Source of data:

This hospital based observational study was conducted over eighteen months on 127 patients diagnosed with carcinoma cervix and referred for MR imaging of pelvis to Department of Radio-Diagnosis at R.L. Jalappa Hospital attached to Sri Devaraj Urs Medical College, Tamaka, Kolar. 103 patients were included in the study after they met the inclusion/exclusion criteria. An informed consent in their own language was taken from individuals for their willingness to participate in the study.

Inclusion Criteria:

All patients with histopathologically diagnosed carcinoma cervix and have undergone MRI evaluation of pelvis.

Exclusion Criteria:

- Claustrophobic
- Metallic implants in pelvis,
- Pacemaker
- Post chemo/radiotherapy.

Method of collection of data:

Baseline data was collected from the patients along with pertinent clinical history, relevant lab investigations and histopathological report. MRI of

i)

RESULTS

pelvis was performed on patients with histopathologically confirmed carcinoma cervix in 1.5 Tesla, 18 channel, MR Scanner (Siemens Magnetom Avanto®).

Parameters used for MRI

The patients are in supine position and following sequences were performed in pelvis:

- Sagittal and axial T1 and T2-weighted fast spin echo,
- Coronal Short Tau Inversion Recovery (STIR);
- Single-shot echo-planner diffusion weighted and

Contrast enhanced study (I.V gadolinium injection) was performed wherever required. Patient's renal function was assessed in the form of blood urea and serum creatinine results and only patients with a normal renal function underwent contrast study (whenever indicated).

The MRI staging of tumor was done as per FIGO guidelines (2009). The clinical and MRI FIGO staging are compared. The final diagnosis was documented and compared whenever available.

Data Analysis:

Collected data was analyzed using chi square test to assess the statistical significance. All newly diagnosed cases of carcinoma cervix received one week of antibiotic therapy following which thorough clinical examination was performed. Chest X-ray, cystoscopy and proctoscopy were performed and clinical stage was assigned based on the 2009 FIGO system.

The following parameters were assessed on MRI:

- a) Corpus uteri involvement
- b) Infiltration of vagina
- c) Parametrial Invasion
- d) Invasion of pelvic side walls
- e) Infiltration of bladder and rectum
- f) Involvement of ureter
- g) Pelvic lymph nodes
- h) Pyometra

Table 1: Age Wise Distribution

Age group (in years)	Number of patients	Percentage (%)
20-29	0	0
30-39	12	12.0
40-49	29	28.0
50-59	28	27.0
60-69	26	25.0
70-79	8	8.0
>80	0	0

The majority of patients in our study was mostly concentrated in the middle age group (80%) i.e. 40-49 years (n=29; 28%), 50-59 years (n=28, 27%) and 60-69 years (n=26; 25%).

Table 2: Parity wise distribution

Parity	Number of patients
1-3	70
4-6	25
7-9	8

Most of the patients (67%) had parity of 1-3 in our study. None of the patients were nulliparous. A total of 72 (73%) out of the 103 patients were postmenopausal, remaining 31 (27%) were premenopausal.

Table 3: Distribution based on clinical presentation

Presentation	Number of patients	Percentage
Discharge per vaginum	93	90%
Post-menopausal bleed	67	65%
Intermenstrual bleed	27	26%
Post coital bleed	8	7%
Asymptomatic	2	1.9%

Table 4: Histopathological distribution

Histopathology	Number of cases	Percentage
Squamous cell carcinoma	98	95.2%
Adenocarcinoma	5	4.8%

Among the 5 patients with adenocarcinoma, 3 are between the age group of 30 – 39 years and remaining 2 patients are between the age group 40 – 49 years.

Table 5: Distribution based on clinical staging

FIGO* Stage	IA	IB	IIA	IIB	IIIA	IIIB	IVA	IVB
Number of patients	0	1	2	47	3	45	5	0
Percentage (%)	0	0.97	1.94	45.63	2.91	43.68	4.85	0

*FIGO –International federation of gynecology and obstetrics

On clinical staging, most of the patient were equally staged as IIB (n=47, 45.6%) and IIIB (n=45; 43.6%) followed by IVA (n=5; 4.8 %). Only one patient (stage IB) had invasive carcinoma with invasion ≥ 5 mm (greater than stage IA) and lesion is limited to the cervix. For 2 patients (stage IIA), involvement was limited to upper two-thirds of the vagina without involving parametrial. For three patients (stage IIIA) the carcinoma involves the lower third of the vagina, with no extension to the pelvic wall. The carcinoma has extended beyond the true pelvis or had involved (biopsy proven) the mucosae of the urinary bladder or rectum in five patients were staged as IVA.

Table 6: Distribution based on MRI staging

Stage	FIGO IA	FIGO IB	FIGO IIA	FIGO IIB	FIGO IIIA	FIGO IIIB	FIGO IVA	FIGO IVB
Number of patients	0	1	8	47	5	5	35	2
Percentage (%)	0	0.97	7.76	45.63	4.85	4.85	33.98	1.94

FIGO –International federation of gynecology and obstetrics

On MRI, majority of the patients were staged under stage IIB (47 patients) and stage IVA (35 patients). Only one patient (FIGO - IB) had invasive carcinoma with invasion ≥ 5 mm (greater than Stage IA) and lesion is limited to the cervix. Eight patients (FIGO - IIA) had involvement of upper two-thirds of vagina without parametrial invasion. Only 2 out of 103 patients showed distant metastasis.

MRI staging after clinical staging have redistributed the cases among IIB and IIIB. Though the number of stage IIB cases remain same but are redistributed to IIIB and IVA. Most of the stage IIIB cases are assigned stage IVA as MRI can clearly delineate the spread of the disease.

On comparing clinical and MR staging, it was found that less than half (n=49) of the cases were staged correctly. It was found that, on clinical staging large number of cases were seen in IIB and IIIB. On MR staging, these cases were found to be redistributed among IIB and IVA.

Table 7: Comparison between clinical and MR staging

Stage	FIGO IA	FIGO IB	FIGO IIA	FIGO IIB	FIGO IIIA	FIGO IIIB	FIGO IVA	FIGO IVB	N=103
MR IA	-	-	-	-	-	-	-	-	0
MR IB	-	-	-	1	-	-	-	-	1
MR IIA	-	1	2	4	-	1	-	-	8
MR IIB	-	-	-	36	1	10	-	-	47
MR IIIA	-	-	-	1	1	3	-	-	5
MR IIIB	-	-	-	-	-	5	-	-	5

MR IVA	-	-	-	4	1	25	5	-	35
MR IVB	-	-	-	1	-	1	-	-	2
Total	0	1	2	47	3	45	5	0	103
FIGO – International federation of gynecology and obstetrics									
MR – Magnetic resonance									
N – Total number of patients									

On comparing clinical staging with MR staging, it revealed that 49 cases were correctly staged clinically. 20 patients were over staged and 34 patients were under staged clinically.

Table 8: Cases correctly staged, under staged & over staged clinically.

MR Stage	N=103	Correctly staged	Under staged clinically	Over staged clinically
MR IA	0	-	-	-
MR IB	1	0	0	1
MR IIA	8	2	1	5
MR IIB	47	36	0	11
MR IIIA	5	1	1	3
MR IIIB	5	5	0	0
MR IV A	35	5	30	0
MR IV B	2	0	2	0
Total	103	49	34	20
MR – Magnetic Resonance N – Total number of patients				

Histopathological correlation was only available for 56 patients up to MR stage IIB. On histopathological correlation, it was found that MR staging was 100% sensitive up to stage IIB. There were disparity between clinical staging and histopathological correlation.

Table 9: Comparison of histopathological, MR & clinical FIGO staging.

Stage	Histopathology	MRI	Clinical
IA	0	0	0
IB	1	1	1
IIA	8	8	2
IIB	47	47	41
IIIA	0	0	1
IIIB	0	0	11
IVA	0	0	0

IVB	0	0	0
Total	56	56	56
MRI – Magnetic resonance imaging			

In our study, clinically no patients were diagnosed with cervical intraepithelial neoplasia and the same was correlated with MRI. One patient was diagnosed as stage IB on MR imaging and on histopathological examination, the lesion showed no evidence of extension of the disease beyond the cervix. This patient was clinically over staged as IIB. Eight patients were staged as IIA on MR imaging. Out of these eight patients only two was correctly staged clinically as IIA. Vaginal invasion was missed in one patient and hence was under staged as stage IB. Five cases were over staged clinically and among them, four cases were staged IIB as they were presumed to invade parametrium. One patient was staged as IIIB due to deranged renal function test; however it was later proved to be a case of chronic kidney disease and not because of pelvic wall extension or hydroureteronephrosis. Eight cases staged as IIA on MR correlated well with the histopathological findings, giving a sensitivity of 100%.

On MR imaging 47 patients were correctly staged as IIB. But on clinical staging, only 36 of these patients were correctly staged and 11 of them were over staged. Among these 11 patients, one was staged IIIA and rest 10 were staged IIIB. A total of 35 cases were staged as IVA and two cases were staged IVB. Among the 35 cases of IVA, 12 cases had isolated bladder involvement, five cases had isolated rectal

involvement and rest of the 18 cases had involvement of both urinary bladder and rectum.

Cystoscopy showed evidence of bladder mucosal involvement in five patients and on MR imaging mucosal involvement was seen in 30 patients and one patient showed infiltration only upto bladder smooth muscle. On cystoscopy, bladder invasion was obvious only when there was mucosal invasion and muscle infiltrations were not picked up. Clinically rectal invasion was seen only in four patients who showed evidence of rectal mucosal involvement on proctoscopy. 23 patients on MR imaging showed rectal mucosal infiltration. Six patients had only rectal muscle infiltration and no obvious mucosal involvement. Similar to bladder invasion, rectal invasion is only picked up clinically when there is obvious mucosal invasion. Two patients on MRI showed metastasis to pelvic bones and one of them showed hepatic metastasis as well. Both the cases were under staged clinically as IIB and IIIB. The patient who was staged MRI IIIB had both hepatic and bony metastasis.

Total of 101 (98%) patients out of 103 showed uterine body infiltration. 46 (45%) out of them belong to IIB, 35 (34%) stage IVA. Among the remaining 20 cases, 8 (7%) cases to IIA, 5 (5%) cases to IIIA, 5 (5%) cases to IIIB and 2 cases to IVB.

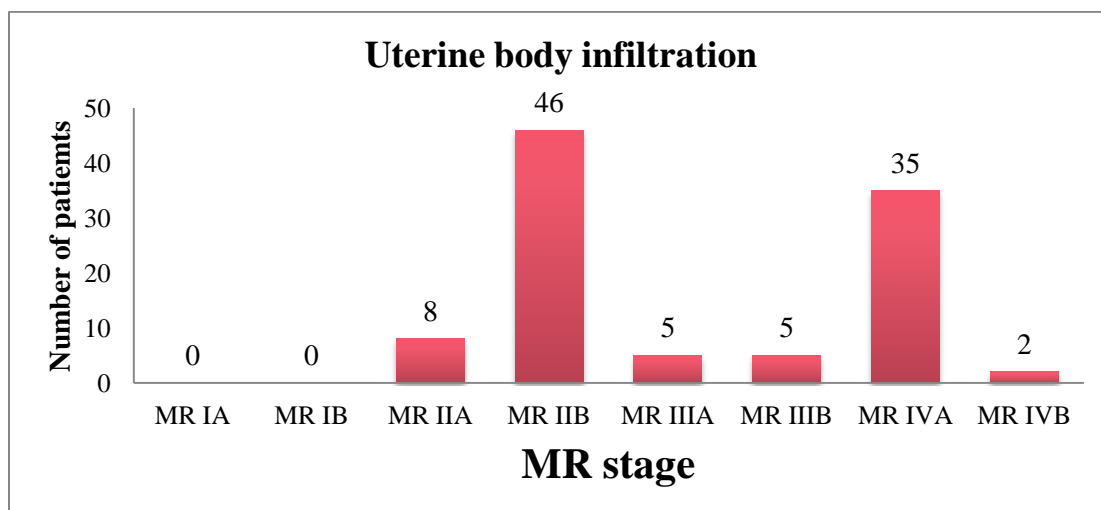


Figure 1: Uterine body infiltration

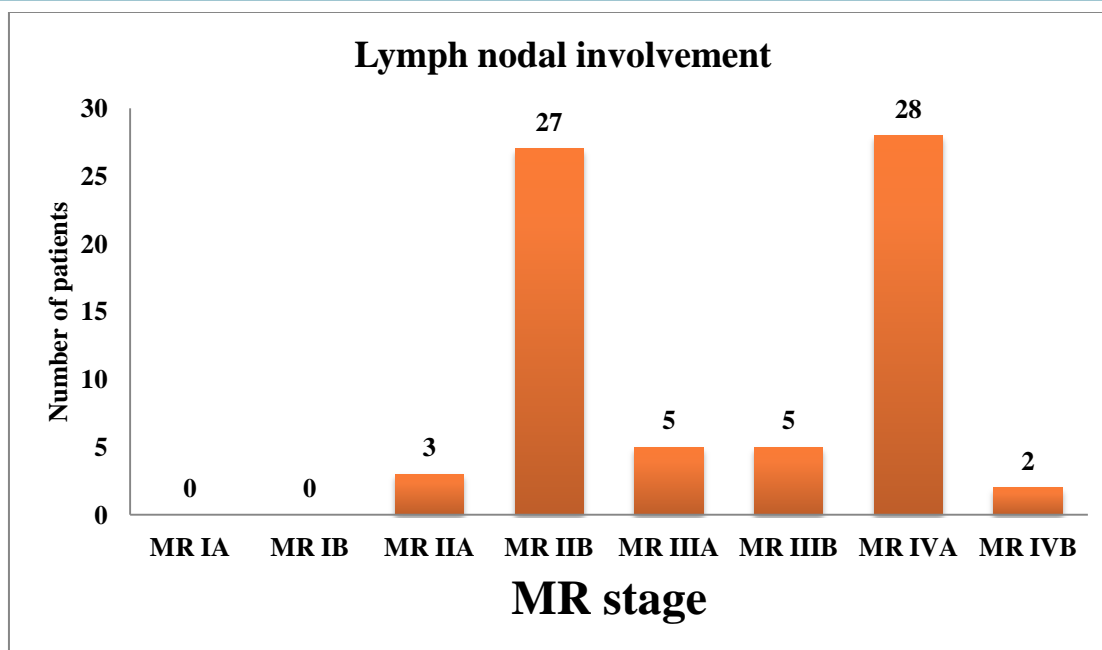


Figure 2: Stage wise distribution of lymph nodal involvement

On MR Imaging, out of the 103 patients, 70 (67%) showed evidence of lymph nodal metastasis. 28 (40%) patients out of these 70 belong to MR stage IVA, 27 (38%) to stage IIB, five (7.1%) each to IIA and IIIB, three (4.2%) to IIA and two (2.8%) to IVB. Patients with disease confined only to the cervix showed no lymph nodal involvement on MR imaging.

Local parameters associated with lymph nodal involvement:

Table 10: Local parameters associated with lymph nodal involvement

Parameter	Number of cases	Percentage (%)
Uterine body	69	98
Vaginal	69	98
Parametrial	67	95
Lateral pelvic wall	5	7
Urinary Bladder	24	34
Rectal	21	30

6 local parameters associated with lymph nodal metastasis were assessed in our study. Uterine body, vaginal and parametrial invasion were the local parameter which were highly associated with lymph nodal metastasis. 69 (98%) out of the 70 patients with lymph nodal involvement had uterine body and vaginal involvement. Parametrial invasion was noted in 67 (95%) out of 70 patients with lymph nodal metastasis which was the next local parameter associated. Urinary bladder involvement and rectal

involvement were noted in 24 (34%) and 21 (30%) out of the 70 patients with lymph nodal metastasis respectively. Only five patients (7%) with lateral pelvic wall involvement were associated with lymph nodal metastasis.

DISCUSSION

The International Federation of Gynecology and Obstetrics (FIGO) staging system updated in 2009 is commonly used for treatment planning but is inadequate in the evaluation of prognostic factors like

tumor volume and nodal status. Magnetic Resonance Imaging (MRI) is the preferred imaging modality for cervical cancer.

Staging plays an important role in prognosis as well as treatment planning. Prognosis of the disease at the time of diagnosis depends on the volume and extent of disease.

The sample size in our study was 103 biopsy proven cases of carcinoma cervix. Majority of the women (73%) in our study were postmenopausal and in middle age group (80%) i.e. 40-49 years (n=29), 50-59 years (n=28) and 60-69 years (n=26). Most of the women (67%) had a parity of 1-3. Discharge per vaginum was the most common presentation with which patients presented in our study.

A study was conducted on 50 patients for the assessment of diagnostic efficacy of diffusion weighted (DWI) sequence in the imaging of carcinoma cervix. They concluded that acquiring DWI additional to conventional sequences provided 100% sensitivity and 84.8% specificity for detecting the tumor.

A study on 45 patients with carcinoma cervix was evaluated by Kumar JU *et al.* to assess the need of contrast MRI. The authors concluded that contrast

was needed only in selected patients with ambiguity in plain study. They also documented that, postcontrast T1 weighted sequence has no additional value when compared with unenhanced T1 and T2 weighted imaging.

Stage IA:

Stage IA being micro invasive can only be diagnosed on microscopy and is normal on MR imaging. On routine MR imaging, stage IA shows no abnormal signal. There were no cases of clinical stage IA cervical cancer. According to Kim SH, Chol BI, Lee *et al.*, the resolution of MR is not enough to detect microscopic lesions and therefore lesions from stage IB onwards only can be picked up on MR imaging.

Stage IB:

Stage IB is a clinically invasive lesion confined only to the cervix. Stage IB lesion appears hyperintense on T2 and STIR sequences with evidence of enhancement on post contrast T1 weighted images.

On MRI, one patient was corresponding to stage IB which correlated with histopathology, but this patient was clinically staged as IIB. Hence we had sensitivity and specificity of 100% in detecting stage IB lesions on MRI. One patient was diagnosed as stage IB clinically but on MR imaging it was staged as IIA

Table 11: Correlation with other clinical studies for stage IB

Stage IB	MRI	Histopathology
Present study	1	1
Ruben <i>et al</i>	9	10
Hricak <i>et al</i>	31	36
Togashi <i>et al</i>	12	18

Hricak H have mentioned the most common cause for over staging on MRI could be due to edema/increased vascularity adjacent to the tumor.

Stage IIA:

Stage IIA is extension of the cervical lesion into the proximal two-thirds of the vagina. Disruption of the hypointense vaginal wall with hyperintense lesion on T2 and enhancement on contrast administration were used as signs of vaginal invasion. Similar criteria were used by Togashi K and Hricak H.

There were eight cases diagnosed with stage IIA on MRI of which all were finally staged as IIA on histopathology. However, only two of these patients were staged as IIA clinically. Thus MRI showed 100% sensitivity and specificity in diagnosing stage IIA lesions.

As mentioned before, two patients who were staged as IIA on clinical examination showed signal changes involving the vagina on MR imaging. Hence both the cases were correctly staged as IIA. Among the rest six cases of MRI staged IIA, one case was staged as

IB, four cases were staged as IIB and one case was staged as IIIB.

Togashi K, in their study of 67 patients had three cases of histopathologically confirmed vaginal invasion. On MRI two of these three cases were over staged as IIB and the other one was under staged as IB.

A study conducted by Sheu identified vaginal invasion on MRI in 9 patients, with 2 false negatives and 6 false positives histopathology. The sensitivity and specificity was 82.0% and 84.0% respectively for detection of vaginal invasion of tumor on MRI.

Stage IIB:

Stage IIB is when the lesion is infiltrating into the parametrium without involvement of the lateral pelvic walls. On MRI T2 hypointense stromal ring is seen surrounding the cervix and disruption of this stromal ring with extension of irregular tumor

margins into the parametrium are said to be signs of definitive parametrium invasion.

47 patients on MR imaging showed involvement of the parametrium and hence they were staged as IIB. On clinical staging, 36 of these 47 patients were staged correctly as stage IIB and rest 11 cases were over staged. Among the 11 patients, one was staged as IIIA and ten patients were staged as IIIB. That is on clinical staging of these 11 patients, parametrial invasion was over staged with infiltration to lateral pelvic walls without hydroureteronephrosis in one patient and with hydroureteronephrosis in rest 10 patients. None of these patients were under staged. Our study showed 100% sensitivity and specificity for staging IIB disease on MRI.

Hricak H, in their study have documented that peritumoral edema and increased vascularity adjacent to the tumor can result in hyperintense signal on T2 weighted images and then mistaken for parametrial involvement by the tumor.

Table 12: Correlation with other clinical studies for stage IIB

Stage IIB	MRI	Histopathology	Percentage (%)
Present Study	47	47	100
Hricak	13	17	76
Togashi	17	19	89

Park reported an accuracy of 84.4% compared with histopathology. Two patients were up-staged (6.3%) and three down-staged (9.4%) including one with no visible tumor at MRI. Choi analysed 226 parametrium with an accuracy of 94.0%.

According to Testa MRI provided low sensitivity (2/5, 40.0%) for the presence of parametrial infiltration. Reviewing parametrial invasion, Postema showed that reader 1 reported a sensitivity of 20.0% and a specificity of 97.0%, while reader 2 observed a sensitivity of 60% and specificity of 73%. MRI interpretation might vary according to different radiologists.

Hricak H and Togashi K had false negative cases in their study. The most probable reason being failure to diagnose parametrial invasion as they were microscopic.

Stage IIIA is defined as infiltration to lower third of the vagina with no involvement of the lateral pelvic walls. Clinically there were three patients staged as IIIA but on MR imaging one patient showed evidence of extension of the disease to lateral pelvic wall. One patient showed extension of disease to the adjacent pelvic organ and another showed parametrial invasion but no extension to lower third of the vagina / lateral pelvic wall and or causes hydronephrosis or non-functioning kidneys. No pelvic or para-aortic lymph nodes were involved. MRI was able to detect and accurately stage the disease.

A total of five cases were staged IIIA on MRI, out of which only one was appropriately staged clinically and one was understaged as IIB and three were overstaged as IIIB.

Stage IIIB:

Stage IIIB is defined as extension of the lesion beyond the parametrium with invasion to the lateral pelvic wall. Criteria used in our study were: tumor less than 3 mm from the pelvic side walls, vascular encasement, presence of hydroureter or Increased signal in the adjacent muscles (obturator internus, piriformis and levator ani). Togashi K and Hricak H had used similar criteria in their study for lateral pelvic wall invasion.

In our study, five patients were stage as IIIB on MR imaging whereas clinically 45 patients were labeled as stage IIIB. Among these 45 patients, only five cases were corresponding to MR staging and 14 cases were understaged and 26 cases were overstaged. All the 14 cases had no extension of the disease upto pelvic side wall and among the 26 cases, 25 patient showed adjacent pelvic organ infiltrations and one case had bony metastasis which was not assessed clinically.

A study by Hricak on 57 patients documented 5 stage IIIB carcinoma cervix on MRI of which 4 had extension to lateral pelvic walls on histopathology. Togashi in their study on 67 patients, one patient with stage IIIB disease was understaged as IIB on MR imaging.

We had small number of patients with pelvic lateral walls infiltration and no surgical correlation was available either. However according to literature MRI is better in detecting pelvic side walls infiltration. MRI helps in planning for radiotherapy required.

Stage IVA:

Disruption of normal hypointense wall of urinary bladder or rectum with or without mass protruding into the lumen was considered as invasion and staged as IVA. The presence of bullous edema alone is insufficient to stage tumor as IVA Togashi and Hricak H have done their study based on similar MRI findings as well.

A total of 35 cases were staged as IVA on MRI and 5 cases (14.28%) were staged appropriately on clinical staging. Majority of the cases (n=25; 71.4 %) were staged as IIIB followed by IIB (n=4; 11.4%) and IIIA (n=1; 2.85%).

Urinary bladder involvement:

Among the 35 cases of IVA on MRI, 12 cases had isolated bladder involvement, five cases had isolated rectal involvement and rest of the 18 cases had involvement of both urinary bladder and rectum. Cystoscopy was performed on five patients who showed evidence of bladder mucosal invasion in the form of exuberant growth and mucosal edema. The biopsy from edematous mucosa revealed malignant infiltration. These patients also had symptoms of cystitis and hematuria. On MRI, all patients showed mucosal involvement. Additionally bladder smooth muscle involvement was seen in one patient

Among the five patients who underwent cystoscopy, four patients showed involvement of rectum which was proven by proctoscopy and one patient had isolated bladder involvement clinically. Very large proliferic mass were seen in all cases involving both bladder and rectum. In patients with no clinical symptoms and normal mucosa on cystoscopy, MR plays an important role in proper detection of bladder involvement.

Rectal involvement:

Proctoscopy was done in four patients who had rectal mucosal involvement with symptoms of bleeding per rectum. These patients also showed invasion of urinary bladder mucosa on cystoscopy. On MRI, rectal mucosal involvement was seen in 23 patients, among which 18 patients had both urinary bladder and rectal mucosal invasion. Five patients had isolated rectal invasion.

Table 13: Stage IVA comparison with other studies

Stage IVA	MRI	Cystoscopy
Present Study (n=23)	23	4
Hricak (n=57)	5	3
Togashi (n=67)	1	1

There is less data availability regarding rectal invasion on MRI in patients with carcinoma cervix. Rockall et al, found 10 false positives out of 112 patients with 100.0% sensitivity and 91.0% specificity. According to Rajaram et al., MRI correctly assessed disease invasion into both spaces with accuracy of 88.9% in vesicocervical space and 66.7% for rectovaginal space. Rockall et al., highlighted 13 false positives out of 112 patients with an overall sensitivity of 100.0% and a specificity of 88.0% for bladder invasion detection with MRI20.

Hertel et al. documented sensitivity of 64.0% and specificity of 88.0% for MRI detectable bladder involvement. Postema et al., found sensitivity and specificity of 77.0% and 97.0%, respectively, for bladder invasion on MRI19.

Stage IVB:

Bone spread:

Stage IVB is when there is distant spread of disease beyond pelvis or shows skeletal metastasis. We had two patients who had involvement of pelvic bone on MR imaging and hence were staged as stage IVB. The bone lesions were hyperintense on T2 and STIR sequences and showed evidence of enhancement on post contrast T1 weighted images. The above two MRI staged IVB patients are clinically staged as IIB and IIIB. Both cases however did not have urinary bladder and rectal invasion on MRI. The clinical stage IIIB case also had hepatic metastasis which was detected incidentally on MRI but histopathological confirmation was not available.

Lymphadenopathy:

On MRI, lymph nodal metastasis was found in 70 out of the 103 patients. These lymph nodes were iso to hypointense on T1 weighted images and hyperintense on T2 and STIR weighted sequences with enhancement on post contrast images. Lymph nodes >10 mm in short axis were taken as significant in our study. This criterion was used by Hricak H et al15 and Togashi K et al11 in their study. Patients with disease confined only to the cervix showed no lymph nodal involvement on MR imaging.

In our study we used six different local morphological parameters as the criteria to assess lymph nodal metastasis. These included involvement of –

1. Uterine body,
2. Vagina,
3. Parametrium,
4. Lateral pelvic wall,
5. Rectal mucosa
6. Urinary bladder mucosa

According to our study uterine body and vaginal invasion was associated with lymph nodal metastasis. 69 (98%) out of the 70 patients with lymph nodal involvement had both uterine body and vaginal invasion. Parametrial involvement was the next local parameter which was associated with lymph node involvement. 67 (95%) out of the 70 patients with lymph nodal metastasis had parametrial involvement. In our study it was found that most of the patients with rectal, bladder or bone spread had evidence of lymph nodal spread as well. Hence we concluded that, once the disease has reached stage IV, lymph nodal spread is highly likely.

A recent article mentioned that PET-CT is more accurate than CT and MRI in detection of nodal metastasis greater than 10 mm with false-negative results ranging between 4%–15%.

LIMITATIONS

1. Sample size in our study was only 103. A larger sample size would have been required to conduct a more extensive study.
2. Surgical staging with histopathological confirmation wasn't available in all the cases as surgery is only performed upto stage IIA. This would be an inherent limitation of the study

CONCLUSION

- MRI is encouraged for cervical cancer staging. There seems to be good correlation between MRI and histopathology. There is a high probability of non-extension to parametrium if cervical stromal ring is seen on T2 weighted MRI and good indication of extension to proximal structures.
- Evaluation of carcinoma cervix by MRI accurately predicts the nodal status and the degree of myometrial and parametrial invasion.
- MRI has good tissue contrast; MRI is the preferred imaging technique for tumor detection and invasion evaluation in advanced stage disease. MRI is far superior to CT and ultrasound in preoperative staging of the disease.

- A combined imaging and histopathological approach is warranted in the management of carcinoma cervix.
- Awareness of MRI limitations is crucial in primary cervical cancer staging.
- MRI has been proposed as better alternative for initial screening of cervical cancer instead of cystoscopy and proctoscopy

BIBLIOGRAPHY

1. International Agency for Research on Cancer. GLOBOCAN 2012: Estimated Cancer Incidence, Mortality and Prevalence Worldwide in 2012 [internet]. 2018 [updated 2018; cited 2018 Sep 04]. Available from: http://globocan.iarc.fr/Pages/fact_sheets_population.aspx.
2. Camisão C, Brenna S, Lombardelli K, Djahjah M, Zeferino L. Magnetic resonance imaging in the staging of cervical cancer. *Radiol Bras* 2007;40:207–15.
3. Nicolet V, Carignan L, Bourdon F, Prossmanne O. MR imaging of cervical carcinoma: A practical staging approach. *Radiographics* 2000;20:1539-49.
4. Mahajan M, Kuber R, Chaudhari K R, Chaudhari P, Ghadage P, Naik M R. MR imaging of carcinoma cervix. *Indian J Radiol Imaging* 2013;23:247-52.
5. Vallikad E. Cervical cancer: The Indian perspective. FIGO 26th annual report on the results of treatment in gynecological cancer. *Int J Gynaecol Obstet* 2006;95:S215-33.
6. Chen J, Zhang Y, Liang B, Yang Z. The utility of diffusion-weighted MR imaging in cervical cancer. *Eur J Radiol* 2010;74:e101-6.
7. Kumar JU, Reddy RH, Sinha P, Kodali N, Sreekanth V. MRI evaluation of local extent of carcinoma cervix - is post contrast imaging needed in every case? *J Clin Diagn Res* 2017;11:TC15-8.
8. Kim SH, Choi BI, Lee HP, Kang SB, Choi YM, Han MC et.al. Uterine cervical carcinoma: comparison of CT and MRI findings. *Radiology* 1990;176:45-51.
9. Rockall AG, Ghosh S, Alexander-Sefre F, Babar S, Younis MT, Naz S. Can MRI rule out bladder and rectal invasion in cervical cancer to help select patients for limited EUA? *Gynecol Oncol* 2006;101:244-9.
10. Rajaram S1, Sharma H, Bhargava SK, Tripathi RP, Goel N, Mehta S. Mapping the extent of disease by multislice computed tomography, magnetic resonance imaging and sentinel node evaluation in stage I and II cervical carcinoma. *J Cancer Res Ther* 2010;6:267-71.
11. Hertel H, Köhler C, Elhawary T, Michels W, Possover M, Schneider A. Laparoscopic staging compared with imaging techniques in the staging of advanced cervical cancer. *Gynecol Oncol* 2002;87:46-51.
12. Bhatla N, Aoki D, Sharma DN, Sankaranarayanan R. Cancer of the cervix uteri. *Int J Gynaecol Obstet* 2018;143:22-36