(International Print/Online Journal)

SJIF IMPACT FACTOR: 4.617
GADIF IMPACT FACTOR: 1.49

ISSN (Print): 2209-2870
ISSN (Online): 2209-2862

International Journal of Medical Science and Current Research (IJMSCR)
Available online at: www.ijmscr.com
Volume1, Issue 4, Page No: 102-111
November-December 2018

IJMSCR

Comparative Evaluation of HRCT of Temporal Bone with Non-EP DWI MRI Sequences for Evaluation of Cholesteatoma in Patients with CSOM

Dr. Kajal Ramendranath Mitra, Dr. Raunak Ravindra Thakare*, Dr. Avinash Parshuram Dhok, Dr.Vikrant Vishnuji Bhende, Dr.Pulak Bhagwat Bansal, Dr. Madhura Vijay Bayaskar

[1] M.D. (Radiodiagnosis), Professor and Dean, [2] MBBS, Junior Resident.
[3] M.D. (Radiodiagnosis), Professor and Head of Department
[4] MBBS, Junior Resident [5] MBBS, Junior Resident [6] MBBS, Junior Resident
Department Of Radiodiagnosis and Imaging,
NKP Salve Institue of Medical Sciences and Lata Mangeshkar Hospital,
Digdoh Hills, Hingna Road, Nagpur, Maharashtra, India

Corresponding Author:
Dr. Raunak Ravindra Thakare
Radiology Department, NKP Salve Institue Of Medical Sciences And Lata Mangeshkar Hospital,
Digdoh Hills, Hingna Road, Nagpur, Maharashtra, India
440019

Type of Publication: Original Research Paper
Conflicts of Interest: Nil

ABSTRACT

Introduction:

Middle ear cholesteatoma is potential serious middle ear disease due to its erosive potential along ossicles and bony wall of middle ear cavity. Certain patterns of bone erosion are specific, but CT attenuation does not allow differentiation from other inflammatory middle ear diseases. Diffusion-weighted imaging is highly specific due to high keratin content of cholesteatomas.

The aim of the present study was to compare Non-EP DWI and HRCT findings in patients of CSOM suspected of cholesteatoma with intra-operative findings.

Materials and Methods:

A prospective study of 40 patients carried in the Department of Radio-diagnosis, NKP SIMS Nagpur. All CSOM cases suspected of cholesteatoma on otoscopic examination were evaluated by Non- EP DWI and HRCT temporal bone before tympanomastoid surgery. Radiological findings were correlated with intra-operative findings.

Results:

Non-EP DWI and HRCT accurately predicted the presence of cholesteatoma in 35 of 36 (97.2%) and 33 of 36(91.6%) patients, respectively. The sensitivity, specificity, and positive and negative predictive values of Non-EPI DWI were 97.2%, 100%, 100%, and 80%, respectively.

However, sensitivity, specificity, and positive and negative predictive values of HRCT were 91.6%, 50%, 94.2%, and 40%, respectively.

Conclusion:

Newer non-EP DWI techniques with thinner section acquisition and decreased susceptibility artifacts allow detection of even small cholesteatoma lesions.

Non-EP DWI is highly sensitive and specific for cholesteatoma diagnosis as compared to HRCT temporal bone. Non-EP DWI can accurately detect primary cholesteatomas especially in absence of bony erosion in HRCT temporal bone.

Keywords: Cholesteatoma, high resolution computed tomography, mastoidectomy,non-echoplanar diffusion weighted magnetic resonance imaging.

INTRODUCTION

Cholesteatomas of the Middle ear is an ectopic keratinized epithelial tissue which grows inside the mucosa-lining of middle ear cavity and desquamates leading to accumulation of keratin and epithelial debris. Cholesteatoma has erosive potential along the ossicles and bony walls of the middle ear cavity, which is because of the inflammatory response that leads to activation of osteoclastic activity. It has

serious intracranial and labyrinthine complications, so elective treatment is surgery, which aims at eradicating disease with simultaneous preservation of anatomy and function. (1)

There are two types of cholesteatoma, acquired type of cholesteatoma and congenital type of cholesteatoma. Acquired cholesteatomas which generally occur in the middle ear cavity and mastoid, whereas the congenital type of cholesteatomas or epidermoids can occur in other locations, which includes the cerebellopontine angle, calvarium, suprasellar cistern and multiple sites in the temporal bone. Only 2% of middle ear cholesteatomas consist of congenital cholesteatomas.(2)

Most of the middle ear cholesteatomas (98%) are acquired. These types are usually related to chronic inflammatory disease of middle ear combined with disturbed ventilation of the middle ear. Various theories have been proposed but the most accepted pathogenic mechanism is invagination of tympanic membrane leading to retraction pockets owing to eustachian tube dysfunction.(3)

In an attic cholesteatoma which is the most common form of acquired cholesteatoma, in which pars flaccida located posteriorly and superiorly, invaginates toward the Prussak space. Growing cholesteatoma cause erosion of the scutum and displacement of medial ossicles which is specific findings at computed tomography (CT). Pars tensa cholesteatoma is a less common type of acquired cholesteatoma, also called sinus cholesteatomas that extend toward the posterior tympanic recesses (sinus tympani and facial recess) and from there to the medial epitympanic space causing displacement of lateral ossicular chain.(4)(5)

Congenital type of middle ear cholesteatoma is less frequent (2%), and has a variable location in the temporal bone. When it is located in the middle ear cavity, a whitish retrotympanic mass at otoscopy is seen behind an intact eardrum, and otoscopic diagnosis may be difficult. Histologically, they are identical to congenital epidermoid cysts which are located elsewhere (skull base, meninges, spinal canal, brain) and are produced due to trapping of ectoderm during fetal development.(6)(7)(8)

Complications of cholesteatomas are mainly because of bony erosion. Erosion is basically thought to be due to relative mechanical pressure and adjacent granulation tissue leading to release of an osteoclast stimulator or collagenase production. Bony erosion can result in ossicular chain destruction leading to conductive hearing loss, labyrinthine fistulas with sensorineural hearing loss and vertigo, facial nerve canal erosion and facial paralysis, and intracranial complications like meningitis and abscess.(9)(2)

High-resolution CT is the method of choice for imaging the cholesteatoma of the middle ear(10). In patients with cholesteatoma, high-resolution CT is able to demonstrate the extent of tumor tissue in relation to the ossicular chain, the epitympanic space, the mastoid cavity, and the labyrinthine structures. Osseous erosion and destructions are also reliably seen. If neither a soft-tissue mass nor bony destructions are seen High-resolution CT has a high negative predictive value. However, high-resolution CT is not able to differentiate cholesteatoma from other soft-tissue masses in the of the middle ear cavity like mucoid secretion, granulation tissue, fibrous tissue, and cholesterol granuloma based on attenuation.(11)(12)

MR Imaging: Novel Techniques:

Diffusion-weighted single-shot spin-echo echo-planar sequences can be useful in the diagnosis of cholesteatomas(13)(14)(15). Irrespective of their type of cholesteatoma, either congenital or acquired, cholesteatomas appear as high signal intensity on DWI. This is attributed partly due to restricted water diffusion (most probably due to the oily consistency of the contained fluid in cholesteatoma) and predominantly because of T2 shine through effect of the lesion as revealed by calculated apparent diffusion coefficient values.(16)

A limitation of spin-echo DWI in the cholesteatoma detection is mainly because of the presence of magnetic susceptibility inhomogeneities present at air/bone interfaces at the base of the skull , especially at the tympanic tegmen(17). Theoretically these artifacts can disguise a cholesteatoma but in reality, they can be distinguished from cholesteatoma due to their rather linear appearing pattern, location outside petrous bone or at the ridge of the petrous bone, and due to their location, which does not correspond to the lesion detected on the HRCT scan. These artifacts can be significantly reduced by parallel imaging

Volume 1, Issue 4; November-December 2018; Page No. 102-111

techniques as well as multishot EPI and FLASH sequences.(18)

Non-EPI DWI Techniques:

Fast spin-echo–based non-EPI DWI techniques have been developed in the past decade by different MR imaging vendors(3)(8)(17)(19). These techniques include single-shot turbo spin-echo DWI, half-Fourier acquisition single-shot turbo spin-echo (HASTE) DWI (Siemens Medical Solutions, Erlangen, Germany), PROPELLER DWI, BLADE DWI (Siemens Medical Solutions), and multishot DWI turbo spin echo. Susceptibility artifacts are mostly minimized by these sequences and also allow thinner sections and higher imaging matrices, yielding higher sensitivities in the 90%–100% range for lesions as small as 2 mm. In comparison with EPI DWI, these non-EPI DWI techniques have improved sensitivity for detection of lesions smaller than 5 mm and allow better delineation of le-sions.(4)(17)(20)(21)

The aim of present study was to compare Non-EPI Diffusion-Weighted Imaging and HRCT findings in patients of Chronic suppurative otitis media (CSOM) suspected of cholesteatoma with intra-operative findings.

MATERIALS AND METHODS:

STUDY DESIGN:

Over a period of 2016 to 2018, patients with clinical diagnosis of Chronic suppurative otitis media (CSOM) suspected of cholesteatoma in the Department of Otorhinolaryngology of NKP SIMS and LMH, Nagpur, who was referred to department of Radio-diagnosis were examined by HRCT temporal bone and MRI.

A total of 40 patients were studied. HRCT temporal bone was performed by using Toshiba Activion 16slice CT machine in direct axial and coronal planes, followed by limited sequence MRI study with Axial PROPELLER diffusion-weighted imaging for all cases. Findings of HRCT temporal bone were recorded and correlative MRI findings were documented. Report of HRCT & limited sequence MRI study of temporal bone was correlated with surgical findings.

INCLUSION CRITERIA

All patients with Chronic suppurative otitis media (CSOM) suspected of cholesteatoma referred from ENT department of our hospital.

EXCLUSION CRITERIA

Subjects were excluded for participation in this study if

1. Patients with previous surgery of middle ear and mastoid.
2. Patients with a history of RTA.
3. Patients with claustrophobia.
4. Patients with metal implants and cardiac pacemakers

MR Imaging Protocol:

MR imaging was performed with a 1.5 HD XT 16 channel 1.5T GE MRI machine by using a dedicated head coil, with patients in a supine position. The imaging parameters utilized for all patients are summarized as below-

A number of slices: 12.

Thickness: 3mms, 0.2 mm interslice spacing.

Matrix: 256x 256, full FOV.

FOV: 22x22 cm.

b value: 0 and 800 s/mm^2.

HRCT imaging protocol:

Scans were acquired in the helical mode to reduce motion artifacts. Scanning parameters used on 16 sliced Toshiba CT machine are 120 kV, 150 mA s, 0.5-mm section thickness. HRCT of the temporal bone is primarily performed in the axial and coronal projections. Axial projections are obtained by serial 0.5mm thin sections of the temporal bone when the patient is supine, with the line joining the infra-orbital rim and external auditory meatus perpendicular to the table and a caudal gantry tilt of 30 degrees. The coronal sections are obtained with the patient in the prone position and a gantry tilt of approximately 30 degrees, perpendicular to the plane joining the inferior orbital rim and the external auditory meatus. The images would be reconstructed with a bone algorithm.

Statistical methods:

Volume 1, Issue 4; November-December 2018; Page No. 102-111

The diagnostic strength of HRCT temporal findings and non-EPI DWI findings were obtained in terms of sensitivity, specificity, positive prediction and negative prediction values. The corresponding statistical significance was also determined using Chi-square test.

All the analyses were performed using R-programming language (R-3.2.3) and statistical significance was tested at 5% level.

RESULTS

Findings of HRCT Examinations:

At surgery, cholesteatoma was present in 36 out of 40 patients (90%) whereas it accurately predicted the presence or absence of cholesteatoma in 33 of 36 patients on HRCT temporal bone. Of 40 patients, we observed 33 true-positive (TP) patients (i.e. Cholesteatoma seen during surgery and pre-operatively diagnosed by HRCT)(figure 1A), 2 false-positive (FP) patient (i.e. no cholesteatoma seen during surgery and pre-operatively diagnosed by HRCT), 2 true-negative (TN) patients (i.e. no cholesteatoma seen during surgery and pre-operatively diagnosed by HRCT), and 3 false-negative (FN) patients (i.e. cholesteatoma seen during surgery but not pre-operatively diagnosed by HRCT)(figure2A). The correlation between preoperative HRCT temporal bone and operative findings is illustrated in Table 1. The sensitivity, specificity, and positive and negative predictive values of HRCT for cholesteatoma were 91.6%, 50%, 94.2% and 40%, respectively. The accuracy of HRCT temporal bone in predicting cholesteatoma pre-operatively was 87.5% with P value 0.111 which is not significant.

Findings of Non-EPI DWI Examinations:

Non-EPI DWI MRI sequence accurately predicted the presence or absence of cholesteatoma in 35 of 36 patients. Of 40 patients, we observed 35 true-positive (TP) patients (i.e. Cholesteatoma seen during surgery and pre-operatively diagnosed by Non-EPI DWI)(figure1B,2B), 0 false-positive (FP) patient (i.e. no cholesteatoma seen during surgery and pre-operatively diagnosed by Non-EPI DWI), 4 true-negative (TN) patients (i.e. no cholesteatoma seen during surgery and pre-operatively diagnosed by Non-EPI DWI), and 1 false-negative (FN) patients (i.e. cholesteatoma seen during surgery but not pre-operatively diagnosed by Non-EPI DWI). The correlation between preoperative Non-EPI and operative findings is illustrated in Table 2. The sensitivity, specificity, and positive and negative predictive values of Non-EPI DWI for cholesteatoma were 97.2%, 100%, 100% and 80%, respectively. The accuracy of Non-EPI DWI in predicting cholesteatoma pre-operatively was 97.5% with P value <0.0001 which is highly significant.

DISCUSSION

The diagnosis of middle ear cholesteatoma is usually made initially on otologic examination. (22)(23)(24)(25)

The high-resolution computed tomography (HRCT) scan is the standard imaging technique for the temporal bone. In cases in which the diagnosis of cholesteatoma is not obvious, computerized tomography may demonstrate a soft tissue mass with its characteristic ossicular erosion and displacement of bone. CT scan can reveal cholesteatoma in hidden areas, such as the posterior tympanic recess, even if it is not detected by otologic examination. A CT scan also provides additional information about congenital anatomic variations that may be encountered during surgery, as well as the complications of cholesteatoma. (22)

In our study, a moderate radio-surgical correlation was noted for the presence or absence of cholesteatoma in the middle ear cavity using soft tissue mass and bony erosions as the radiologic criteria on HRCT temporal bone. At surgery, cholesteatoma was present in 36 out of 40 patients (90%) whereas it was reported in 33 of 36 patients on HRCT scans thereby giving a sensitivity of 91.6%, specificity of 50%, positive predictive value of 94.2% and negative predictive value of 40% for HRCT in detecting cholesteatoma preoperatively. Similar findings were also noted in the study conducted by

Firas Q et al (26), observed that HRCT scan of temporal bone had a good sensitivity of 80% and low specificity of 48% for diagnosing cholesteatoma and in another study by Joselito L. Gaurano et al (27) reported that the correlation of pre-operative CT with surgical and histopathological findings was 97%. N W C Chee et al (28) also showed that cholesteatoma can be accurately diagnosed by the HRCT scan in the vast majority of cases. They considered

Volume 1, Issue 4; November-December 2018; Page No. 102-111

nondependent soft tissue mass, typical location (epitympanum and mastoid antrum) and bone erosion as the radiographic criteria for the diagnosis of cholesteatoma and showed that using at least 2 of the 3 features, cholesteatoma could be diagnosed in 94.4% of cases.

Jackler et al (29), reported cholesteatoma was present in 78.6% of cases at surgery on basis of soft tissue mass along with bone erosion on HRCT temporal bone.

The high sensitivity of HRCT in detecting cholesteatoma may be due to the accuracy of HRCT in detecting soft tissue mass with bone erosion. However, low specificity of HRCT temporal bone is due to its inability to differentiate fluid and soft tissue mass based on the attenuation values and also due to the presence of ossicular erosion in some of the cases of the chronic mucosal disease has to be considered.

Single-shot (SS) turbo spin-echo DWI MRI sequence allows the use of a higher imaging matrix and thinner (2 mm) sections and it is associated with fewer susceptibility artifacts. This sequence allows detection of a cholesteatoma as small as 2 mm in an ear that has not undergone surgery. The most recent method for the diagnosis of primary and recurrent cholesteatoma is the multishot fast spin-echo DWI-PROPELLER(Periodically rotated overlapping parallel lines with enhanced reconstruction) technique which is a non -echoplanar sequence. (30)

In our study, cholesteatoma was present in 36 out of 40 patients (90%) at surgery whereas it was reported in 35 of 36 patients on PROPELLER DWI MRI sequence thereby giving a sensitivity of 97.2%, specificity of 100%, positive predictive value of 100% and negative predictive value of 80% for HRCT in detecting cholesteatoma preoperatively. Similar findings were also noted in the study conducted by

Lehmann et al(17)**,** reported similar results in detecting cholesteatoma using PROPELLER DWI with a sensitivity of 96.5%, specificity of 100%, the positive predictive value of 100% and negative predictive value of 96.3%.

Pizzini et al (20), evaluated the value of half-Fourier acquisition single-shot turbo-spin-echo diffusion-weighted magnetic resonance imaging (HASTE DW MRI) using a 3-Tesla machine in diagnosing primary cholesteatoma and relapsing cholesteatoma. They reported a sensitivity of 100%, specificity of 100%, the positive predictive value of 100% and negative predictive value of 100% in detecting cholesteatoma.

Bert De Foer et al (19), conducted a prospective study to evaluate use of Single-shot (SS) turbo spin-echo (TSE) diffusion-weighted (DW) magnetic resonance imaging sequence in detecting congenital or acquired middle ear cholesteatoma. Hyperintense signal on SS TSE DW imaging which was correlating with intraoperative cholesteatoma found in 19 out of 21 patients. They reported a sensitivity of 90%, specificity of 100%, the positive predictive value of 100% and negative predictive value of 96% in detecting cholesteatoma.

In contrast to our study Kasbekar et al(31) , reported sensitivity of 43% , specificity of 92%, PPV 75% and NPV 73% of PROPELLER DWI in middle ear cholesteatoma detection and concluded that PROPELLER sequence is not an ideal form of non-echo planar imaging for middle-ear cholesteatoma detection(46). Results by Kasbekar et al were unsatisfactory because PROPELLER DWI was performed on a 1.5-T system with a low-resolution imaging matrix of 128 × 128, which could reduce sensitivity for detection of smaller lesions. In our study images were acquired with a 1.5-T unit, a 256 × 256 matrix with an eight-channel dedicated head coil which provides high intrinsic SNR.

CONCLUSION

Non-EPI DWI MRI sequence combines the high specificity for keratin-containing lesions with a high sensitivity for detection of small lesions due to thinner sections. Non-EP DWI can accurately detect primary cholesteatomas especially in absence of bony erosion in HRCT temporal bone.

The HRCT temporal bone has good sensitivity for detecting cholesteatoma and can provide a comprehensive pre-operative evaluation of cholesteatoma. It can accurately depict the status of the middle ear structures and it delineates the location and extent of the disease, provides information related to anatomical variations and complications. However, it has low specificity and cannot differentiate between cholesteatoma and other soft tissue masses of middle ear.

Volume 1, Issue 4; November-December 2018; Page No. 102-111

Hence, the use of combine technique, including HRCT temporal bone with only one MRI sequence of Non- Echoplanar DWI can provide a high- quality comprehensive evaluation of cases of CSOM suspected of Cholesteatoma .

TABLES AND FIGURES:

Table 1: HRCT Temporal bone finding with respect to the presence or absence of Cholesteatoma at surgery

	HRCT temporal bone finding	
Operative finding	Erosion (n=35)	No erosion (n=5)
Positive (n=36)	33	3
Negative (n=4)	2	2
Odds ratio	9.7714	
Sensitivity	91.6%	
Specificity	50.00%	
Positive Prediction Value (PPV)	94.2%	
Negative Prediction Value (NPV)	40.00%	
Accuracy	87.50%	
P - value*	0.111 (NS)	

*NS: Not Significant

Volume 1, Issue 4; November-December 2018; Page No. 102-111

Table 2: Non-EPI DWI findings with respect to the presence or absence of Cholesteatoma at surgery

	Non-EPI DWI findings	
Operative finding	Hyper intensity(n=35)	No Hyper intensity (n=5)
Positive (n=36)	35	1
Negative (n=4)	0	4
Odds ratio	-	
Sensitivity	97.2%	
Specificity	100%	
Positive Prediction Value (PPV)	100%	
Negative Prediction Value (NPV)	80.00%	
Accuracy	97.50%	
P - value*	< 0.0001 (HS)	

- *HS: Highly Significant

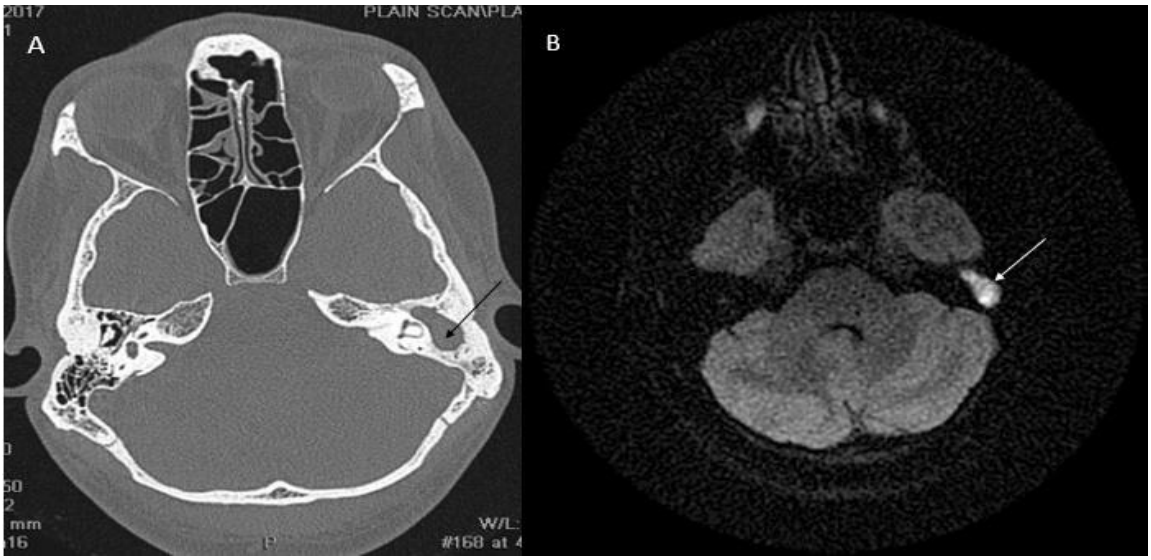

Figure 1A- Axial HRCT Temporal bone showing soft tissue (black arrow) in epitympanum, aditus ad antrum on left side.

Figure1B- Axial non- EPI MRI sequence showing hyperintensity (white arrow) on corresponding section of HRCT temporal bone.

Volume 1, Issue 4; November-December 2018; Page No. 102-111

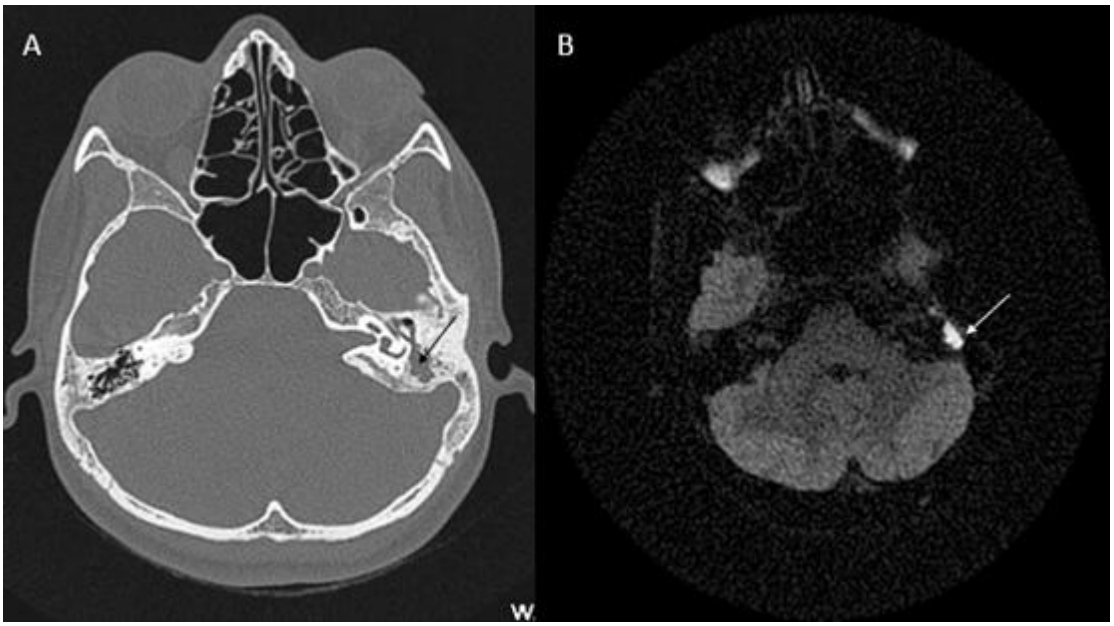

Figure2A- Axial HRCT Temporal bone showing soft tissue (black arrow) in epitympanum, aditus ad antrum on left side.

Figure2B- Axial non- EPI MRI sequence showing hyperintensity (white arrow) on corresponding section of HRCT temporal bone.

REFERENCES:

1. Probst R, Grevers G, Heinrich I. Basic Otorhinolaryngology: a step-by-step learning guide. Georg Thieme, Stuttgart; 2004.
2. Swartz JD. Cholesteatomas of the middle ear. Diagnosis, etiology, and complications. Radiol Clin North Am. 1984;22(1):15–35.
3. Olszewska E, Wagner M, Bernal-Sprekelsen M, Ebmeyer J, Dazert S, Hildmann H, et al. Etiopathogenesis of cholesteatoma. Eur Arch Oto-Rhino-Laryngology Head Neck. Springer; 2004;261(1):6–24.
4. Baráth K, Huber AM, Stämpfli P, Varga Z, Kollias S. Neuroradiology of Cholesteatomas. Am J Neuroradiol [Internet]. 2011 Feb 1;32(2):221 LP-229. Available from: http://www.ajnr.org/content/32/2/221.abstract
5. Verbist BM, Mancuso AA, Antonelli PJ. Chronic otomastoiditis and acquired cholesteatoma. Head and neck radiology. Lippincott Williams & Wilkins Philadelphia, Pa; 2011. p. 756–76.
6. Muller J. Uber den feineran Bau and die Forman der Krankhauten Geschwulste. Berlin G Reimer. 1838;
7. Jahn AF. Cholesteatoma: what is it, how did it get there, and how do we get rid of it? Otolaryngol Clin North Am. 1989;22(5):847–57.
8. Wang R-G, Hawke M, Kwok P. The epidermoid formation (Michaels' structure) in the developing middle ear. J Otolaryngol. 1987;16(6):327–30.
9. Som PM. Parapharyngeal Space In Som PM, Curtin HD (eds): Head and Neck Imaging. St Louis, Mosby; 1996.
10. Alexander JAE, Caldemeyer KS, Rigby P. Clinical and surgical application of reformatted high-resolution CT of the temporal bone. Neuroimaging Clin N Am. 1998;8(3):631–50.
11. Bowdler DA, Parcy P, Blany S. Otoscopic second look intact canal wall mastoid surgery. In: Proceedings Vth International Conference on Cholesteatoma and Mastoid Surgery Roma, Italy: Edizioni Internationali. 1997. p. 795–8.
12. Blaney SP, Tierney P, Oyarazabal M, Bowdler DA. CT scanning in" second look"

Volume 1, Issue 4; November-December 2018; Page No. 102-111

combined approach tympanoplasty. Rev Laryngol. 2000;121(2):79–81.

13. Fitzek C, Mewes T, Fitzek S, Mentzel H, Hunsche S, Stoeter P. Diffusion-weighted MRI of cholesteatomas of the petrous bone. J Magn Reson Imaging An Off J Int Soc Magn Reson Med. Wiley Online Library; 2002;15(6):636–41.
14. Maheshwari S, Mukherji SK. Diffusion-Weighted Imaging for Differentiating Recurrent Cholesteatoma from Granulation Tissue after Mastoidectomy: Case Report. Am J Neuroradiol [Internet]. 2002 May 1;23(5):847 LP-849. Available from: http://www.ajnr.org/content/23/5/847.abstract
15. Stasolla A, Magliulo G, Parrotto D, Luppi G, Marini M. Detection of Postoperative Relapsing/Residual Cholesteatomas With Diffusion-Weighted Echo-Planar Magnetic Resonance Imaging. Otol Neurotol [Internet]. 2004;25(6). Available from: https://journals.lww.com/otology-neurotology/Fulltext/2004/11000/Detection_of_Postoperative_Relapsing_Residual.5.aspx
16. Aikele P, Kittner T, Offergeld C, Kaftan H, Hüttenbrink K-B, Laniado M. Diffusion-Weighted MR Imaging of Cholesteatoma in Pediatric and Adult Patients Who Have Undergone Middle Ear Surgery. Am J Roentgenol [Internet]. American Roentgen Ray Society; 2003 Jul 1;181(1):261–5. Available from: https://doi.org/ 10.2214/ ajr.181.1.1810261
17. Lehmann P, Saliou G, Brochart C, Page C, Deschepper B, Vallée JN, et al. 3T MR Imaging of Postoperative Recurrent Middle Ear Cholesteatomas: Value of Periodically Rotated Overlapping Parallel Lines with Enhanced Reconstruction Diffusion-Weighted MR Imaging. Am J Neuroradiol [Internet]. 2009 Feb 1;30(2):423 LP-427. Available from: http://www.ajnr.org/content/30/2/423.abstract
18. Van den Brink JS, Watanabe Y, Kuhl CK, Chung T, Muthupillai R, Van Cauteren M, et al. Implications of SENSE MR in routine clinical practice. Eur J Radiol. Elsevier; 2003;46(1):3–27.
19. De Foer B, Vercruysse J-P, Pilet B, Michiels J, Vertriest R, Pouillon M, et al. Single-shot, turbo spin-echo, diffusion-weighted imaging versus spin-echo-planar, diffusion-weighted imaging in the detection of acquired middle ear cholesteatoma. Am J Neuroradiol. Am Soc Neuroradiology; 2006;27(7):1480–2.
20. Pizzini FB, Barbieri F, Beltramello A, Alessandrini F, Fiorino F. HASTE Diffusion-Weighted 3-Tesla Magnetic Resonance Imaging in the Diagnosis of Primary and Relapsing Cholesteatoma. Otol Neurotol [Internet]. 2010;31(4). Available from: https://journals.lww.com/otology-neurotology/Fulltext/2010/06000/HASTE_Diffusion_Weighted_3_Tesla_Magnetic.10.aspx
21. Bailey BJ, Johnson JT, Newlands SD. Head & neck surgery--otolaryngology. Vol. 1. Lippincott Williams & Wilkins; 2006.
22. Mafee MF, Levin BC, Applebaum EL, Campos M, James CF. Cholesteatoma of the middle ear and mastoid. A comparison of CT scan and operative findings. Otolaryngol Clin North Am [Internet]. University of Illinois Hospital, Chicago.; 1988;21(2):265–93. Available from: http://europepmc.org/abstract/MED/3357696
23. Phelps PD, Lloyd GAS. Cholesteatoma. In: Diagnostic Imaging of the Ear. Springer; 1990. p. 117–33.
24. Buckingham RA, Valvassori GE. Tomographic evaluation of cholesteatomas of the middle ear and mastoid. Otolaryngol Clin North Am. United States; 1973 Jun;6(2):363–78.
25. Buckingham RA, Valvassori GE. Tomographic and surgical pathology of cholesteatoma. Arch Otolaryngol. United States; 1970 May;91(5):464–9.
26. Saeed HAASR. The role of preoperative CT scan in patients with chronic otitis media. 2009;(December 2007):807–9.
27. Gaurano JL, Joharjy IA. Middle ear cholesteatoma: characteristic CT findings in

Volume 1, Issue 4; November-December 2018; Page No. 102-111

64 patients. Ann Saudi Med [Internet]. King Faisal Specialist Hospital and Research Centre; 2004;24(6):442–7. Available from: https://www.ncbi.nlm.nih.gov/pubmed/15646162

28. Chee NWC, Tan TY. The value of pre-operative high resolution CT scans in cholesteatoma surgery. Singapore Med J. Citeseer; 2001;42(4):155–9.

29. Jackler RK, Dillon WP, Schindler RA. Computed tomography in suppurative ear disease: A correlation of surgical and radiographic findings. Laryngoscope [Internet]. John Wiley & Sons, Ltd; 2018 Nov 25;94(6):746–52. Available from: https://doi.org/10.1288/00005537-198406000-00004

30. De Foer B, Vercruysse J-P, Bernaerts A, Maes J, Deckers F, Michiels J, et al. The value of single-shot turbo spin-echo diffusion-weighted MR imaging in the detection of middle ear cholesteatoma. Neuroradiology. Germany; 2007 Oct;49(10):841–8.

31. Kasbekar A V, Scoffings DJ, Kenway B, Cross J, Donnelly N, Lloyd SWK, et al. Non echo planar, diffusion-weighted magnetic resonance imaging (periodically rotated overlapping parallel lines with enhanced reconstruction sequence) compared with echo planar imaging for the detection of middle-ear cholesteatoma. J Laryngol Otol [Internet]. 2010/11/29. Cambridge University Press; 2011;125(4):376–80.

Volume 1, Issue 4; November-December 2018; Page No. 102-111