(International Print/Online Journal)

SJIF IMPACT FACTOR: 4.617
GADIF IMPACT FACTOR: 1.49

ISSN (Print): 2209-2870
ISSN (Online): 2209-2862

International Journal of Medical Science and Current Research (IJMSCR)
Available online at: www.ijmscr.com
Volume1, Issue 4, Page No: 06-10
November-December 2018

IJMSCR

A Study to Correlate Most Common Morphological Abnormalities with Female Monosomy X (Turner Syndrome)

***Dr Shabana Borate, Dr Suresh Gangane, Dr Prasad Kulkarni**
[1'3]Associate Professor, Genetics Division Department of Anatomy Grant Govt. Medical College, Mumbai, India.
[2] Professor and Head, Department of Anatomy, Terna Medical College, Nerul, Navi Mumbai

Corresponding Author:
Dr Shabana Borate
Associate Professor,
Genetics Division Department of Anatomy Grant Govt. Medical College Mumbai, India

Type of Publication: Original Research Paper
Conflicts of Interest: Nil

ABSTRACT
Turner syndrome (monosomy of chromosome X) is the most commonly encountered genetic abnormalities in the females. Its incidence is about 1 in 2500 of live births. It includes many clinical features such as short stature, webbed neck, cubitus valgus and shield chest. Short stature can be one of the most common presenting symptoms of Turner syndrome. Although ovarian function and chances of fertility cannot be improved an attempt can be made by treating a girl child early to increase her height by few centimeters by growth hormone therapy and providing hormonal replacement therapy to attain secondary sexual characteristics and by proper genetic counseling.

Keywords: Turner syndrome, Karyotype, Monosomy X, Short stature, Webbing of neck, Primary amenorrhoea, DSD.

INTRODUCTION

Turner syndrome is a variable entity caused by complete or partial absence of one of the X chromosome in females [1] . It has a incidence of between 1 in 2000 and 1 in 5000 live born girls. [2]. More than 99% of 45, X conceptuses abort spontaneously, accounting for one fifth of all spontaneous abortions Paternal nondisjunction accounts for 70% of live born cases with a 45,X chromosomal complement [3].

Cytogenetically, the TS is characterized by sex chromosome monosomy (45, X) in phenotypically female individuals and this karyotype is found in 50-60% of the cases. The remaining cases are mosaics with a 45, X cell line plus a normal line (46, XX), 47, XXX and/ or structural anomalies (isochromosomes of the long arm, dicentric chromosomes, deletion of the short arm or ring chromosomes). This is found in 30% of the cases [4] [5]. Finally, mosaicism with a cell line presenting a normal or abnormal Y chromosome (isochromosome of the long arm and dicentric chromosomes) is identified in 6-11% of patients with TS [4] [5].

Most of the genetic disorders have significant effect on growth of an individual. Turner syndrome is an important consideration in phenotypic females with short stature and especially growth failure, because shortness may be the presenting feature of the syndrome; other physical abnormalities are variably expressed [6]. Virtually all girls with Turner syndrome have short stature, with an average adult height about 20 cm shorter than predicted by the mid-parental height [2] [7].

The aim of the study is to provide accurate diagnosis and to provide information to the patient and family regarding natural history, prognosis, available treatment, genetic basis in short stature patients because of its higher possibilities of being associated with Turner syndrome.

Material and Methods

This study was conducted in Genetics Division, Grant Govt. Medical college and Sir J.J.Group of hospitals Mumbai for the period of 3 years. The study subjects were 270 referred patients for karyotyping

with presenting symptoms of primary amenorrhoea, secondary amenorrhoea and suspected disorder of sexual development (DSD) in the age group of 0 to 30 years. Out of these referred patients 32 subjects revealed pure monosomy X (Turner karyotype). We studied these patients to find out association of most common abnormal clinical features with Turner karyotype.

Inclusion criteria – Subjects who revealed 45,XO karyotype.

Exclusion criteria – Subjects with mosaicism, structural abnormalities, numerical abnormalities other than monosomy and normal karyotype are excluded from this study.

This study was approved by Institutional Ethics committee.

Methods

Complete history of patient was taken, clinical examination was carried out. 2 ml of peripheral venous blood was collected in a heparinised vaccutainer under all aseptic precautions. Peripheral lymphocyte culture was set and GTG banding technique was applied and metaphases were analyzed [8] using Lucia software.

Observations and Results

Cytogenetic analysis

Out of 270 referred subjects; 32 subjects on cytogenetic analysis revealed pure monosomy X i.e 45,XO karyotype (fig1). Out of these 20(62.5%) were primary amenorrhoea patients; 6(18.75%) were secondary amenorrhoea patients and 6(18.75%) were referred as suspected disorder of sexual development (DSD).

Age at presentation

The maximum number of subjects with presenting symptom as primary amenorrhoea and karyotype pure monosomy X were presented in the age group of 12 to 18 years i.e 11 (55%) and 9(45%) were presented in the age group of above 18 years.

The number of subjects with presenting symptom as secondary amenorrhoea and karyotype pure monosomy X presented in the age group of 12 to 18 years were 03 (50%) and 03(50%) were presented in the age group of above 18 years.

The maximum number of subjects with presenting symptom as suspected DSD and karyotype pure monosomy X were presented in the age group of 0 to 06 years i.e 4 (66.67%) and 2(33.33%) were presented in the age group above 18 years.

We had further evaluated clinical features in these subjects to find out most commonly associated abnormal clinical feature in pure monosomy of X chromosome (Table 1).

Discussion

Turner syndrome (TS) arising from partial or complete X chromosomal monosomy is the most

common genetic disorder in females [9]. Failure to transmit a paternal sex chromosome to a gamete is the most common cause of a 45,X chromosomal complement.70- 80% of patients with 45,X karyotype are conceived from a sperm lacking a sex chromosome [2]

In the present study total 32 subjects revealed pure monosomy X karyotype. Out of which 20(62.5%) were presented with primary amenorrhoea; 6(18.75%) with secondary amenorrhoea; and 6(18.75%) subjects suspected of disorders of sexual development. Suri et al. (1995) observed 45,X to be the most frequently occurring karyotype in (44.4%) [3].V. Kalavathi et al (2010) reported, 45,X pattern as the most common anomaly in 22.7% of the cases of PA [10].

In the present study the highest number of referral was in the age group of 0 to 6 years i.e 66.66% of suspected DSD subjects followed by primary amenorrhoea subjects in the age group of 12 to 18 years i.e 55%.

Short stature may either be proportionate or disproportionate. One of the causes for proportionate short stature is chromosomal disorder [11]. Monosomy for short arm of X leads to short stature and patients usually have the stigmata of Turner syndrome [12] [13].

In the present study we reported short stature as the most common clinical feature in 19 out of 32 (56.25%) subjects followed by webbed neck in 15 (46.87%) and shield chest in 11(34.38%), while cubitus valgus and short neck reported in 10 (1.25%). Gap between first and second toe in 7(21.87%); lymphoedema in 2 (6.25%) and high arch palate in

Volume 1, Issue 4; November-December 2018; Page No. 06-10

2(6.25%) of subjects with pure monosomy X. This study goes with V.Kalavathi et al 2010 who also reported short stature as most common feature of Turner syndrome followed by shield chest [10]. J.Vijayalakshmi et al (2010) reported 18% of the patients with primary amenorrhea [14].

Malcom A et al (1965) reported short stature in 100%, shield chest in 80%, webbing of neck in 54% and lymphoedema in 39% in subjects with gonadal dysgenesis [12]

Conclusion

The main interest is to achieve a greater final height by growth hormone treatment when the patient has diagnosed earlier . But in many cases patients seeks medical advice at the time of puberty by that time it is very late to start any treatment because growth is possible as long s epiphyses remain open. Replacement therapy with estrogens is indicated, but there is little consensus about the optimal age at which to initiate treatment. The psychological preparedness of the patient to accept therapy must be taken into account. Considering all these facts Genetic counseling of patient as well as parents to be carried out for proper treatment and rehabilitation of patient.

References

1. Rimoin DL, Emery AEH. Emery and Rimoin's principles and practice of medical genetics. [Internet]. Churchill Livingstone Elsevier; 2007 [cited 2017 Sep 10].
2. Nussbaum, Robert L; McInnes, Roderick R; Huntington FW. Thompson & Thompson Genetics in Medicine. Elsevier. 2016.
3. Suri M, Kabra M, Jain U, Sanders V, Saxena R, Shukla A, et al. A clinical and cytogenetic study of Turner syndrome. Indian Pediatr [Internet]. 1995 Apr;32(4):433–42.
4. Ribeiro SC, Tormena RA, Peterson TV, Gonzáles M de O, Serrano PG, de Almeida JAM, et al. Müllerian duct anomalies: Review of current management. Sao Paulo Med J. 2009;127(2):92–6.
5. Patsalis PC, Sismani C, Hadjimarcou MI, Kitsiou-Tzeli S, Tzezou A, Hadjiathanasiou CG, et al. Detection and incidence of cryptic Y chromosome sequences in Turner syndrome patients. Clin Genet [Internet]. 1998 Apr;53(4):249–57.
6. Seaver LH, Irons M, American College of Medical Genetics (ACMG) Professional Practice and Guidelines Committee. ACMG practice guideline: genetic evaluation of short stature. Genet Med [Internet]. 2009 Jun;11(6):465–70.
7. Borate S, Gangane S. Multiple Cell Lines in A Short Stature Patient.International Journal of Current Research. 2016;45–6.
8. Gangane SD. Human genetics. 5th Edn.India: Elsevier 2016.
9. Athar AM, Idiculla J, John S, Hubert H. Three decades of turner ` s syndrome – An experience from a South Indian genetic center.Al Ameen J Med Sci 2012;5:394–7.
10. Kalavathi V, Chandra N, Renjini Nambiar G, Shanker J, Sugunashankari P, Meena J, et al. Chromosomal abnormalities in 979 cases of amenorrhea: A review. Int J Hum Genet. 2010;10(1–3):65–9.
11. O.P. Ghai, Piyush Gupta, V.K.Paul,Growth and Development,Ghai Essential Pediatrics,6t edition,2007
12. Ferguson-Smith M a. Karyotype-Phenotype Correlations in Gonadal Dysgenesis and Their Bearing on the Pathogenesis of Malformations. J Med Genet. 1965;2(2):142–55.
13. Kaur A, Mahajan S, Singh JR. Cytogenetic Analysis in Cases with Sex Anomalies.Int J Human Genet 2004;4(3):167–71.
14. Vijayalakshmi J, Koshy T, Kaur H, Andrea Mary F, Selvi R, Deepa Parvathi V, et al. Cytogenetic Analysis of Patients with Primary Amenorrhea. Int J Hum Genet [Internet]. 2010 ;10(3):71–6.

Volume 1, Issue 4; November-December 2018; Page No. 06-10

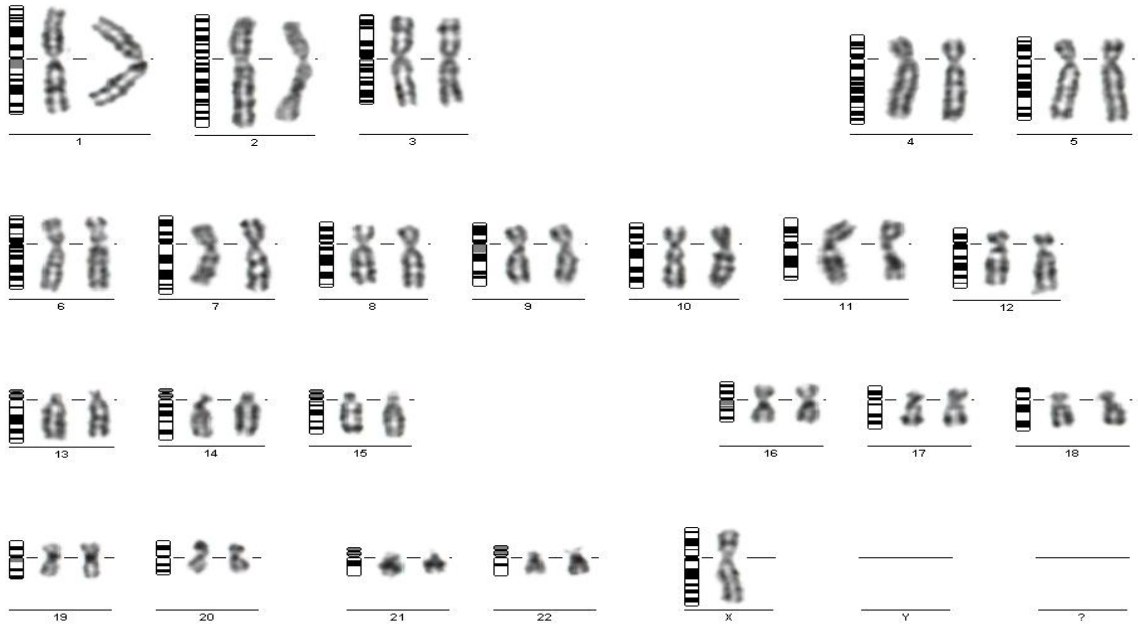

Fig1: Karyotype showing 45, XO chromosomal complement.

Table 1: Percentage distribution of abnormal clinical features in study subjects with 45,XO chromosomal complement.

Clinical Features	Primary Amenorrhoea (n= 20)		Secondary Amenorrhoea (n=06)		Suspected DSD (N=06)		Total (N=32)	
	No.	%	No.	%	No.	%	No.	%
Small neck	06	30	01	16.66	03	50	10	31.25
Webbed neck	08	40	04	66.66	03	50	15	46.87
Cubitus valgus	07	35	02	33.33	01	16.66	10	31.25
Shield chest with widely placed nipples	03	15	02	33.33	06	100	11	34.38

Volume 1, Issue 4; November-December 2018; Page No. 06-10

Short stature	09	45	04	66.66	06	100	19	56.25
Gap between first and second toe	02	10	04	66.66	01	16.66	07	21.87
Lymphedema	00	00	00	00	02	33.33	02	6.25
High arched palate	01	05	00	00	01	16.66	2	6.25

Volume 1, Issue 4; November-December 2018; Page No. 06-10